

Klinika Chirurgii i Onkologii Dziecięcej  
Uniwersytetu Medycznego w Łodzi

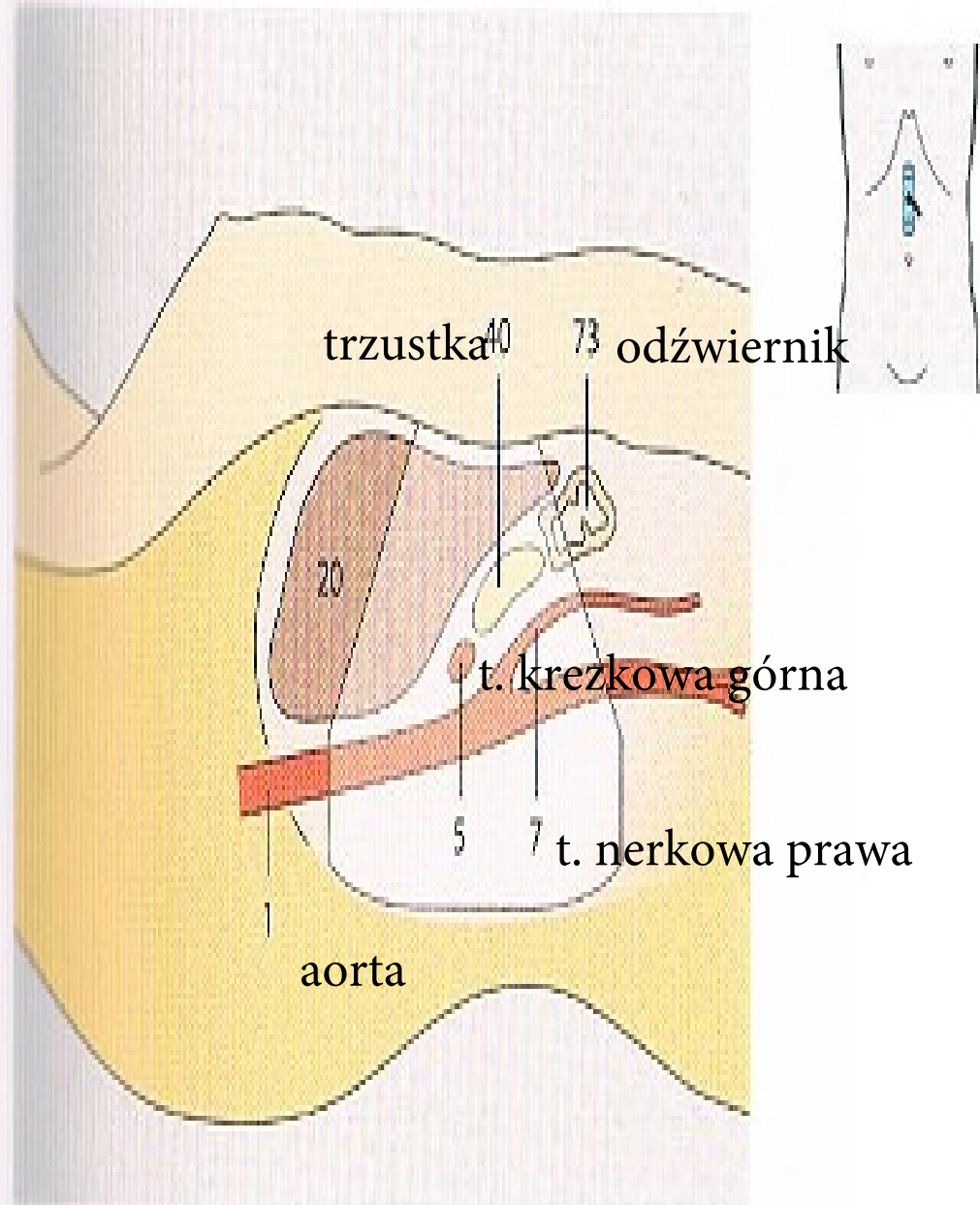
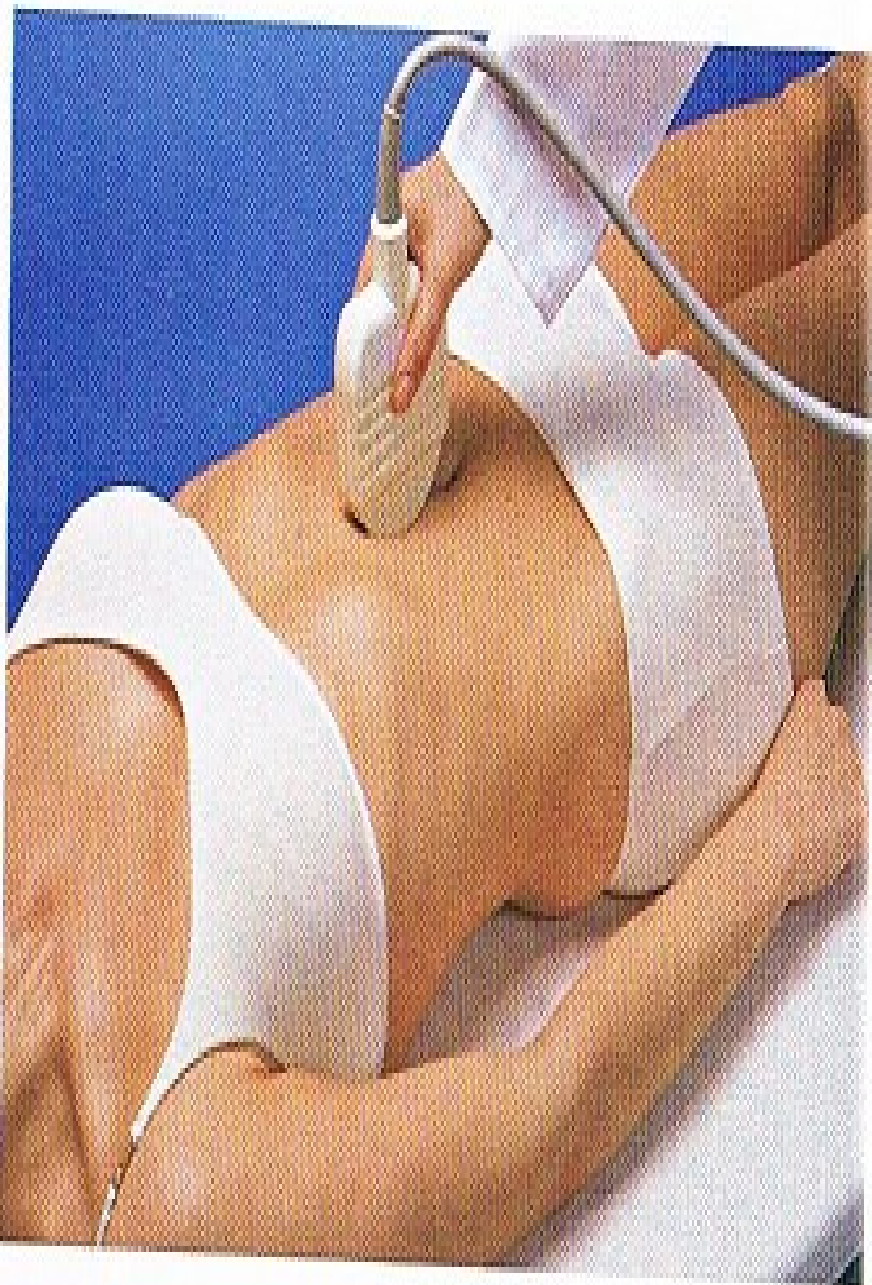


# Podstawy Ultrasonografii dla studentów cz. II anatomia ultrasonograficzna

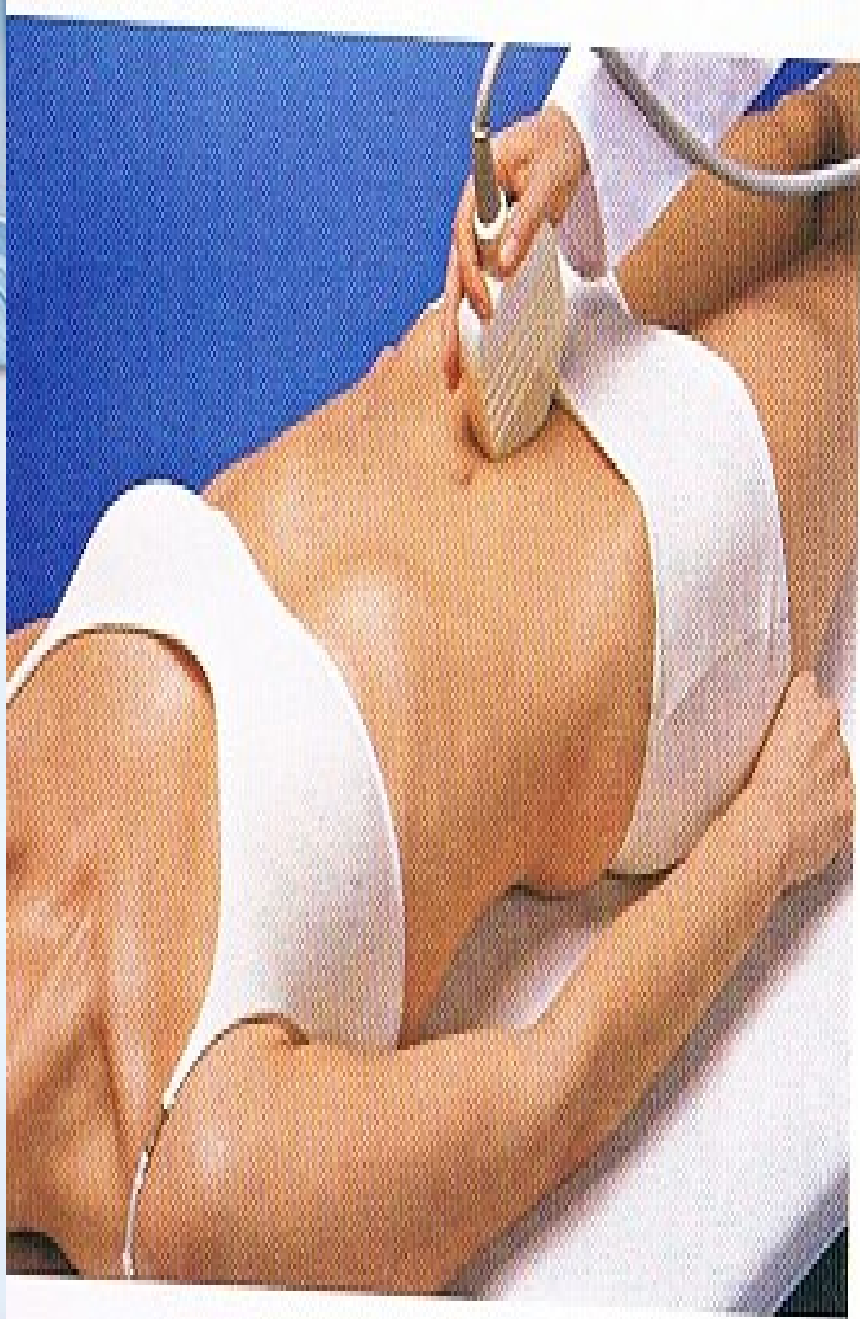
Joanna Gajęcka

Opiekun koła: Dr n. med. Janusz Jabłoński


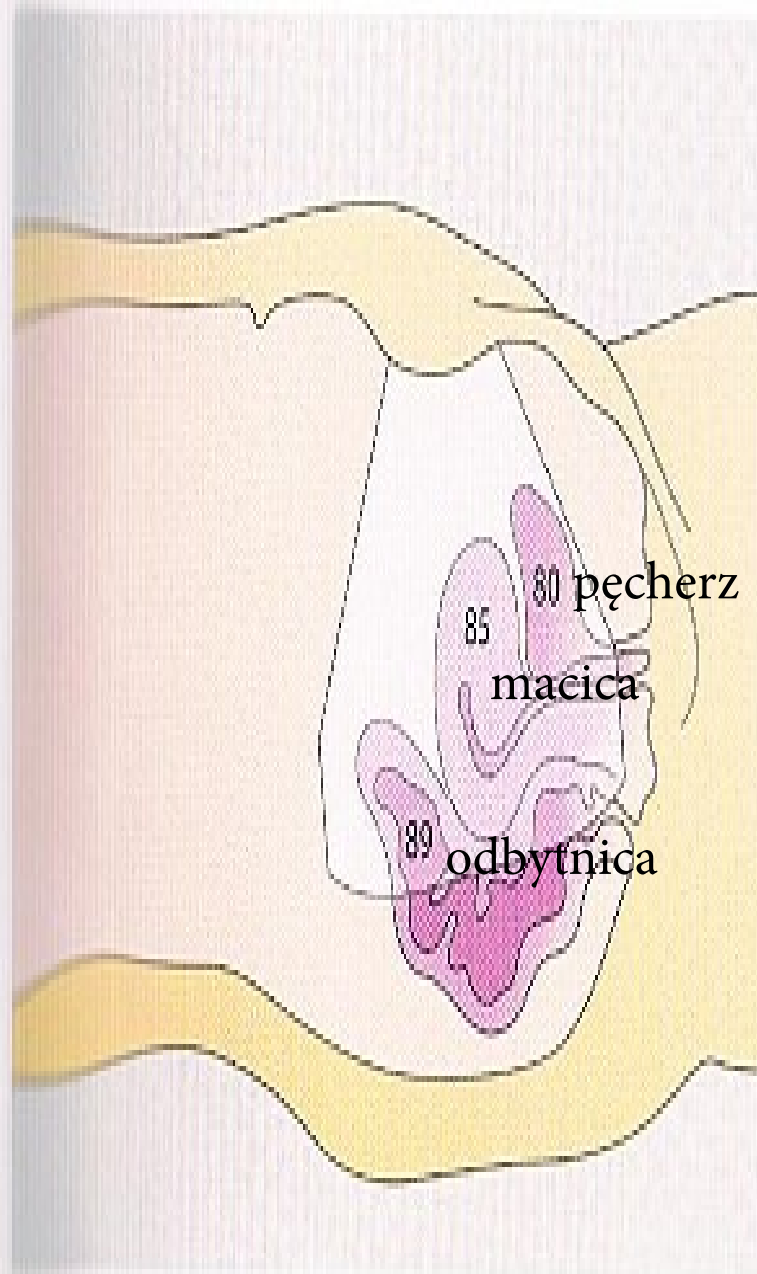
Kierownik kliniki: Prof. dr n med. Ewa Andrzejewska

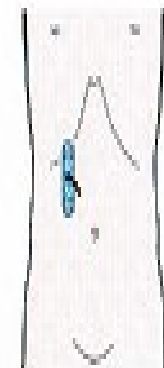
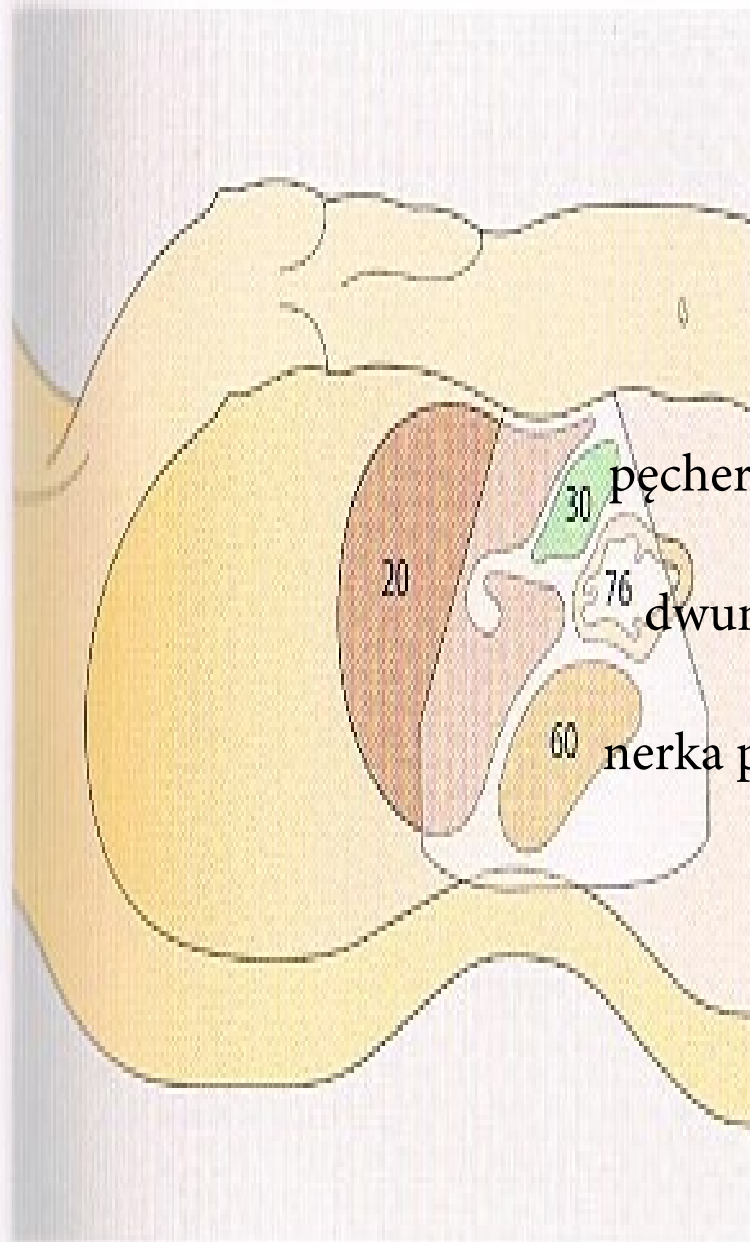
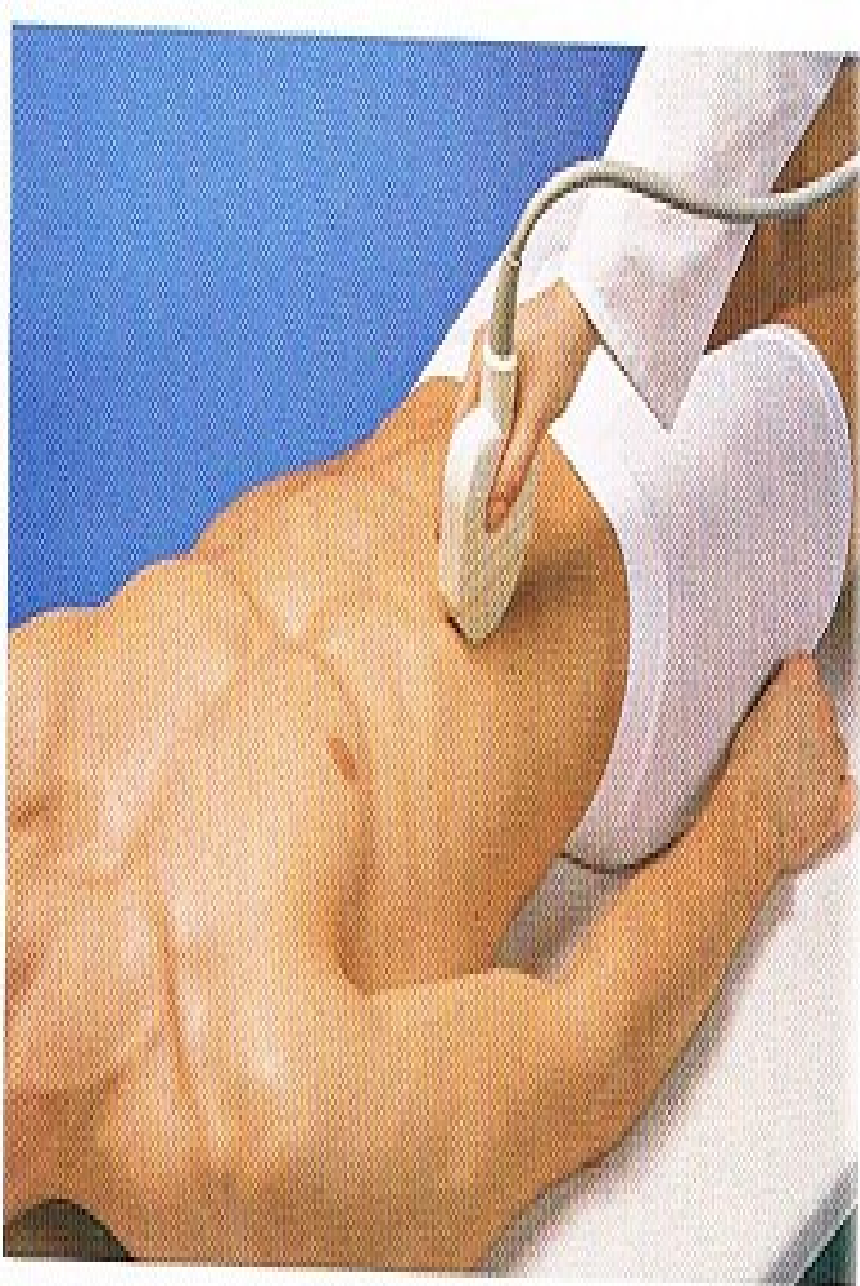


➤ Nadbrzusze, przekrój podłużny w linii środkowej ciała



Podbrzusze, przekrój podłużny w linii pośrodkowej ciała



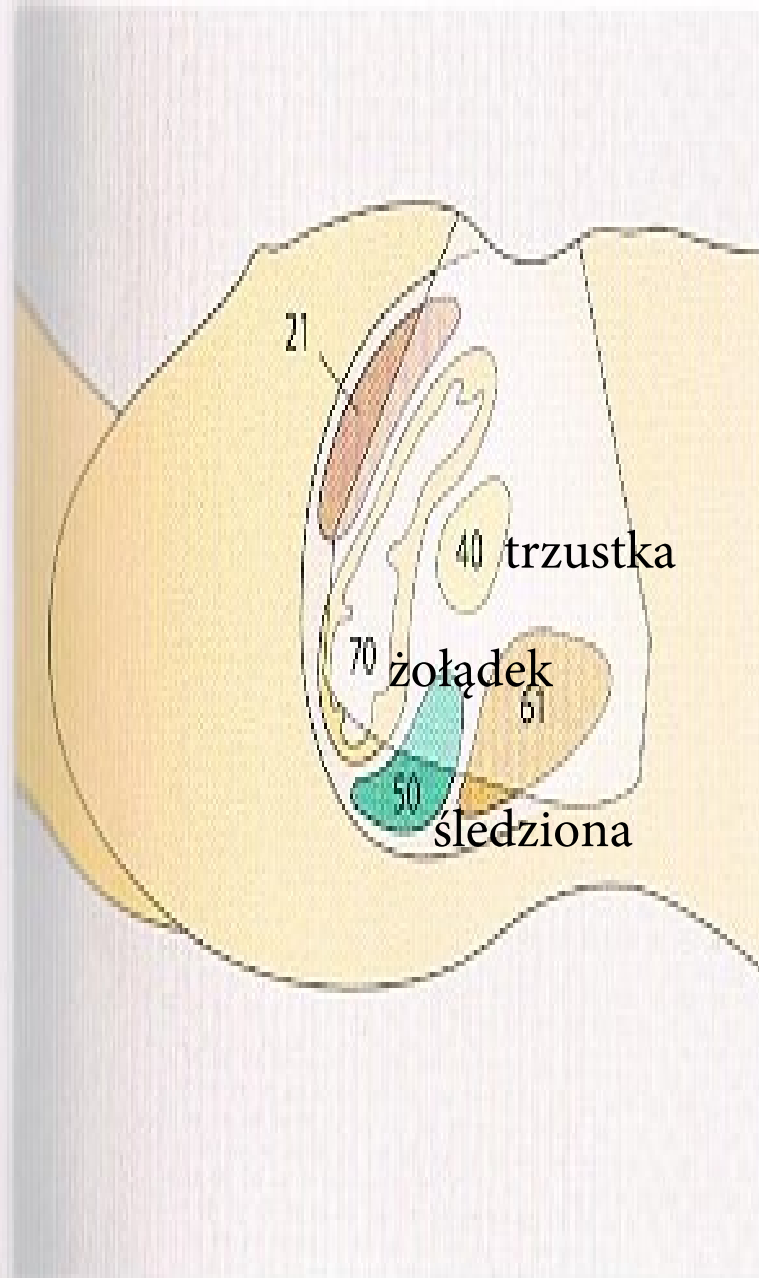
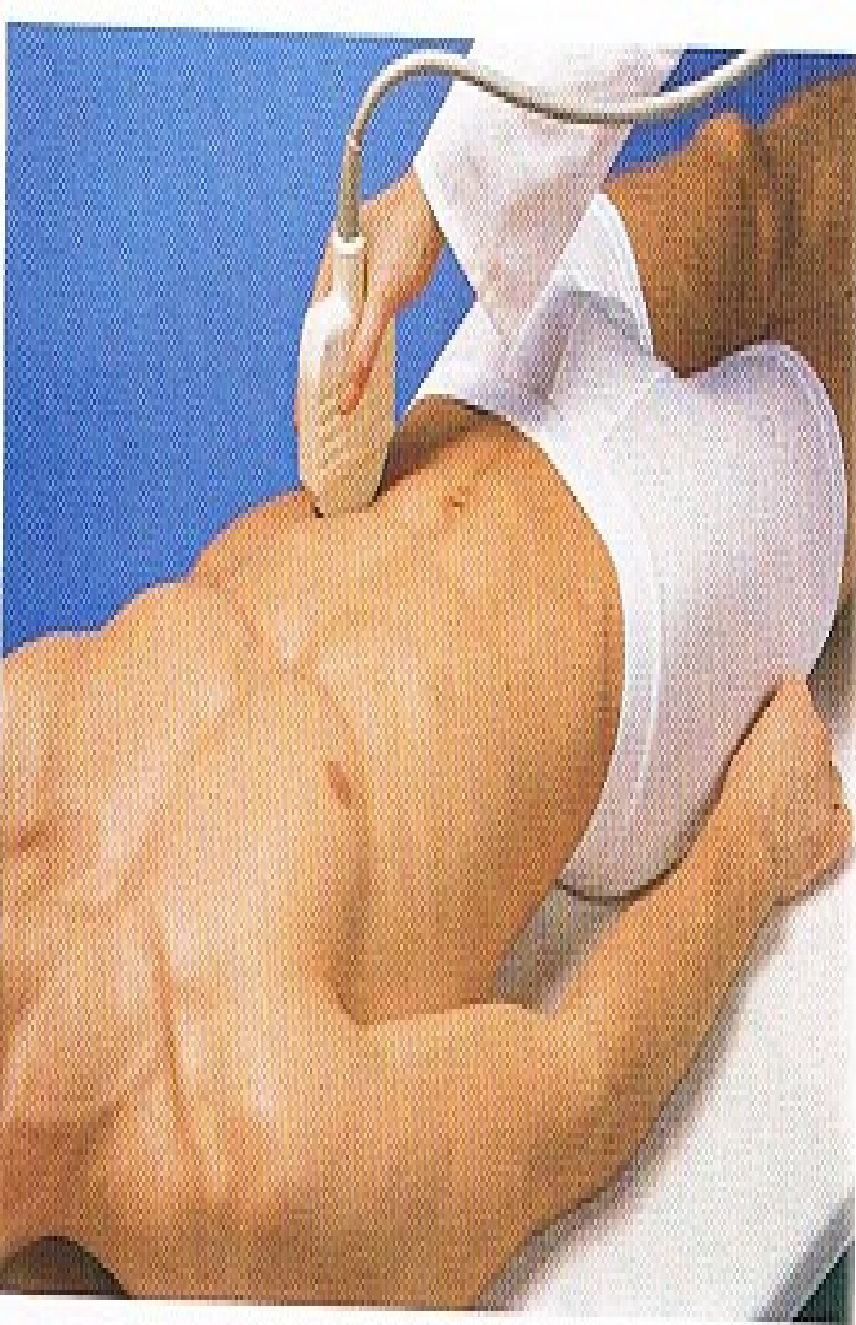


pęcherzyk żółciowy

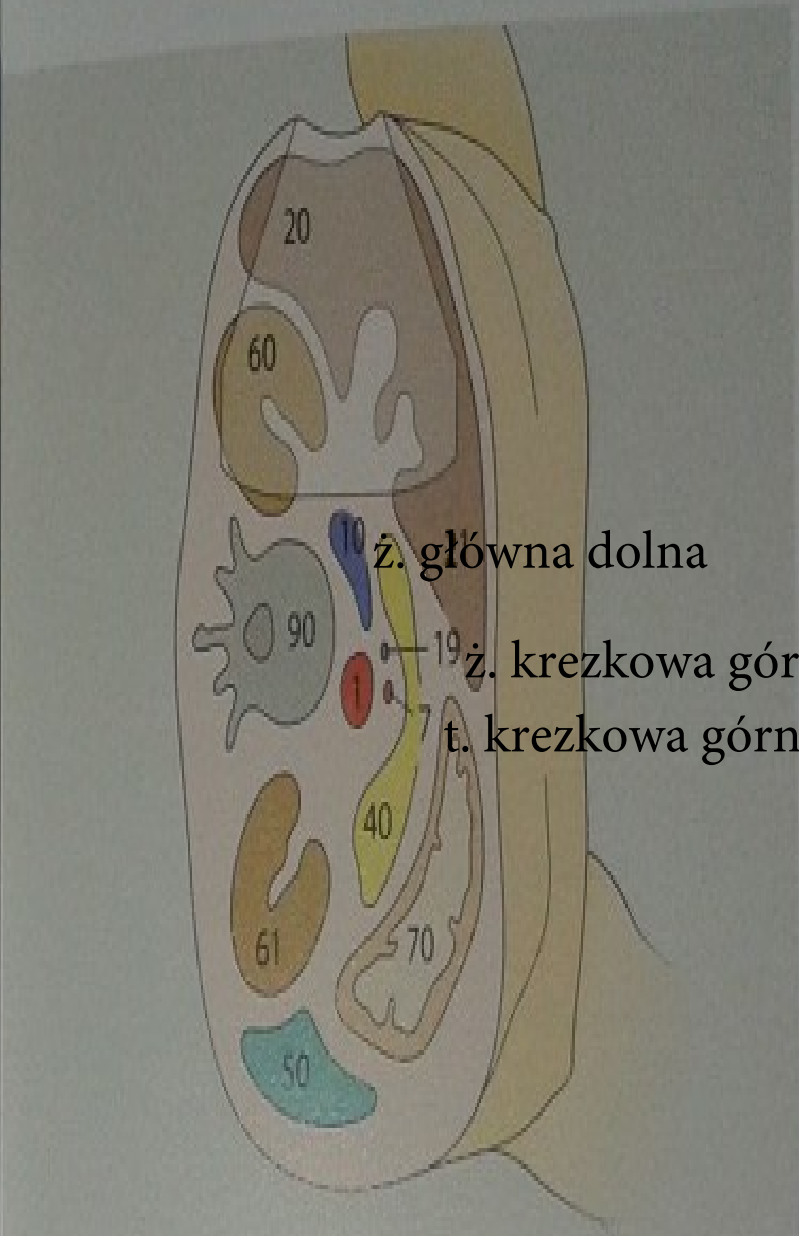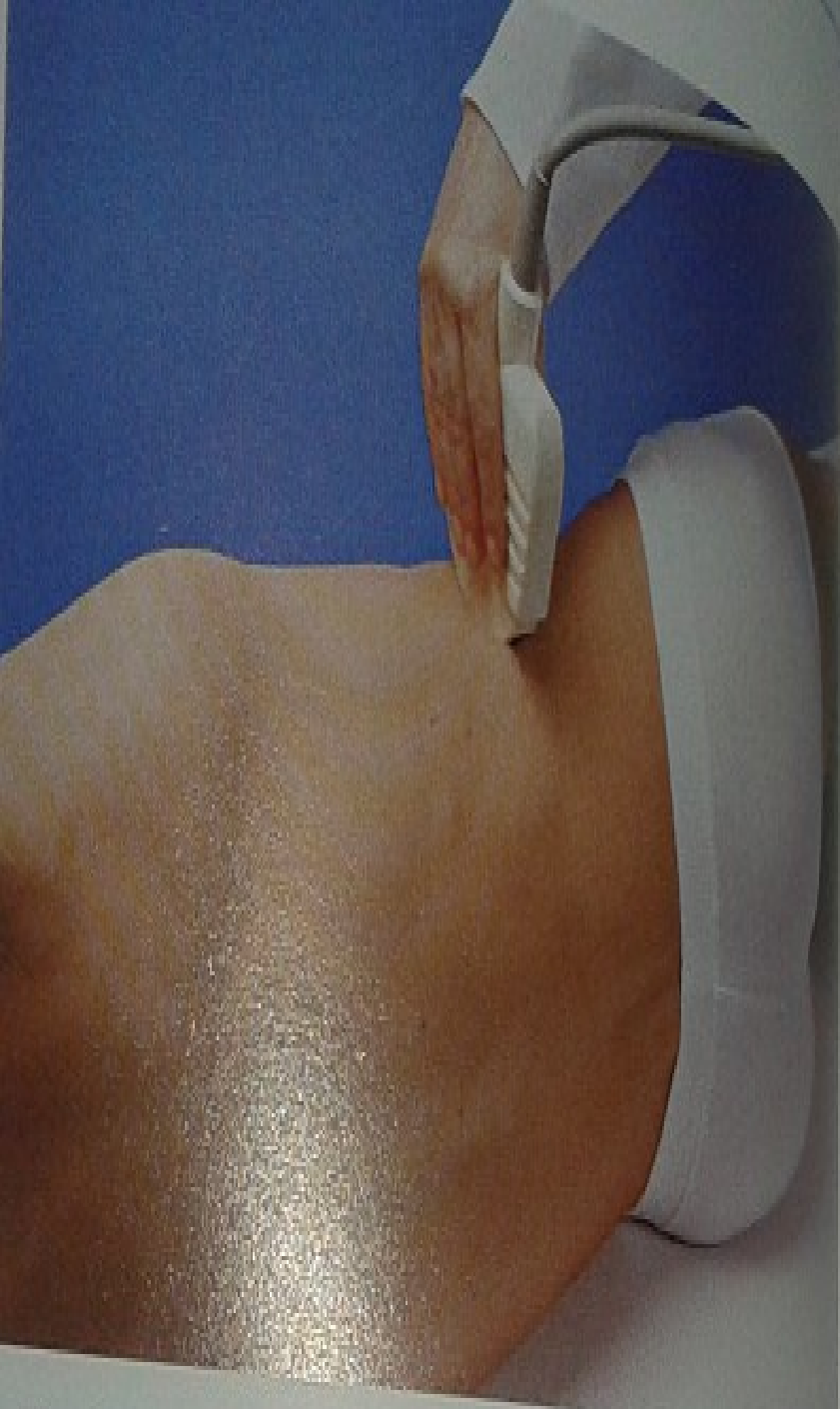dwunastnica

nerka p

➤ Nadbrzusze, przekrój podłużny w linii środkowo-obojętkowej prawej



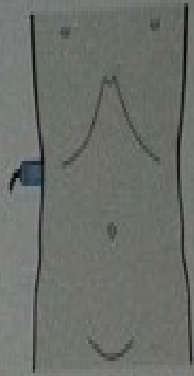
➤ Nadbrzusze, przekrój podłużny w linii środkowo-obojętkowej lewej

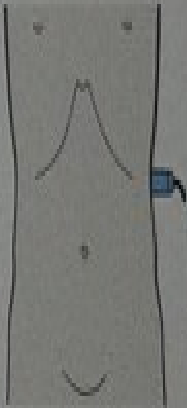
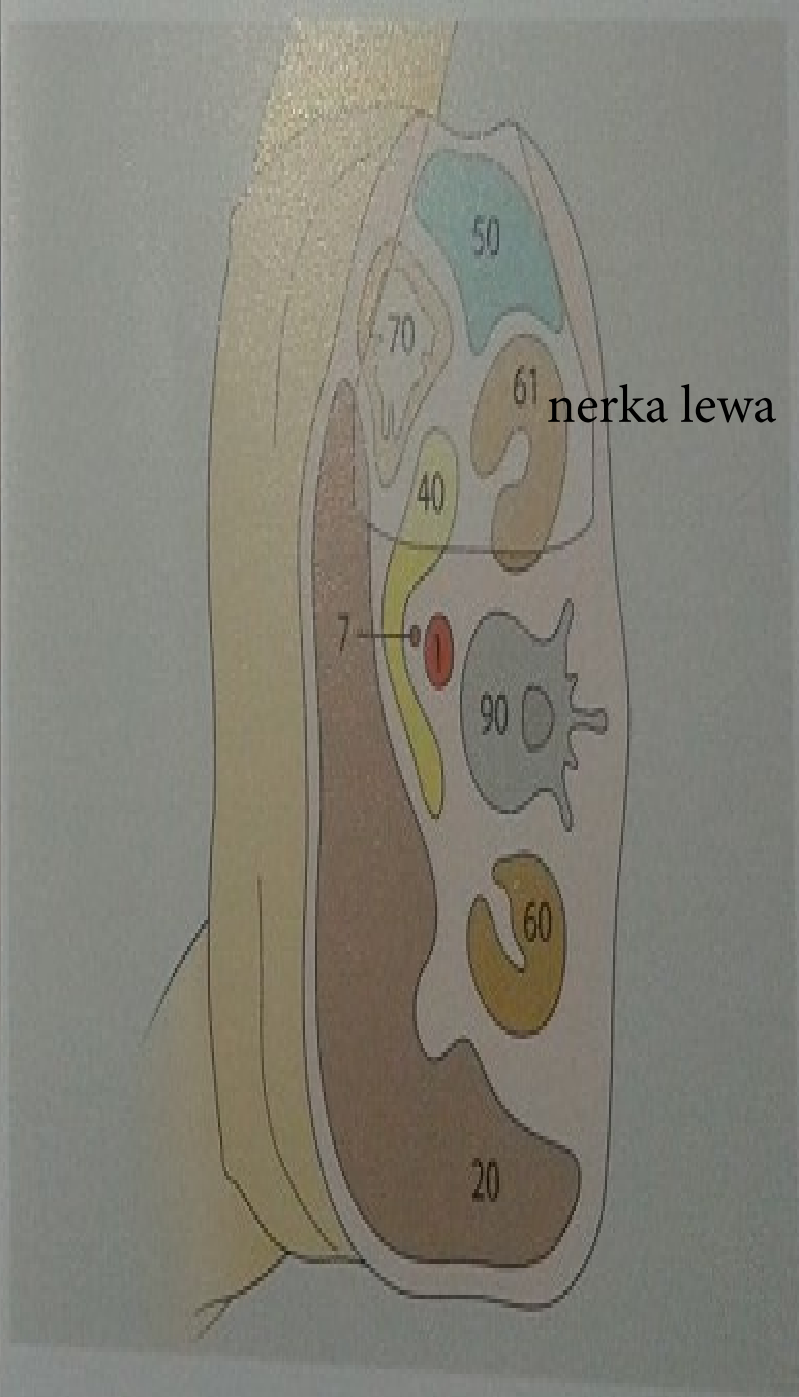
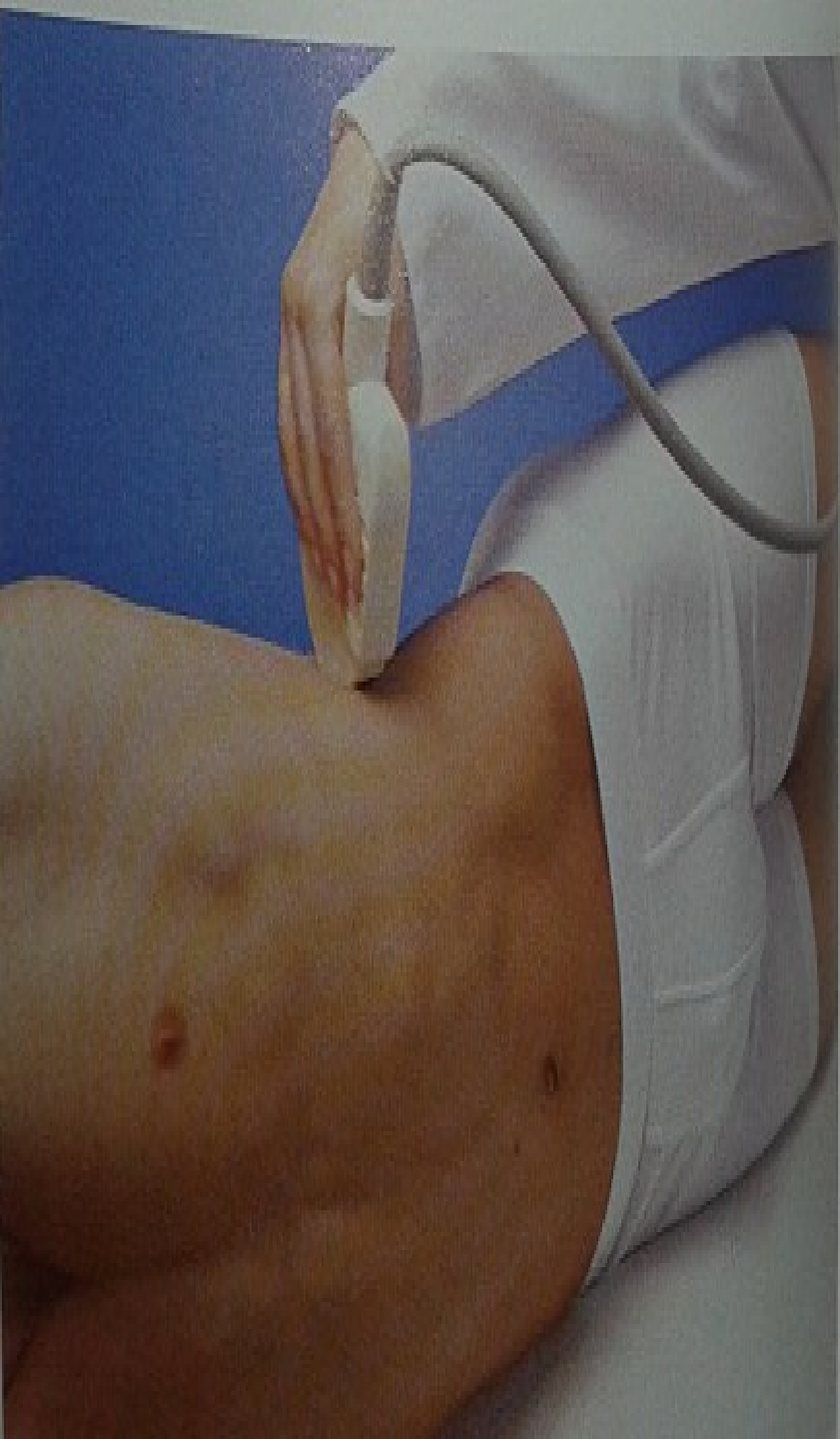

ż. główna dolna

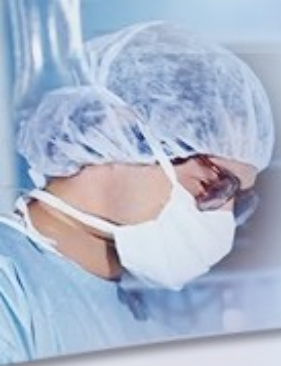ż. kręzkowa górna

t. kręzkowa górna





nerka lewa

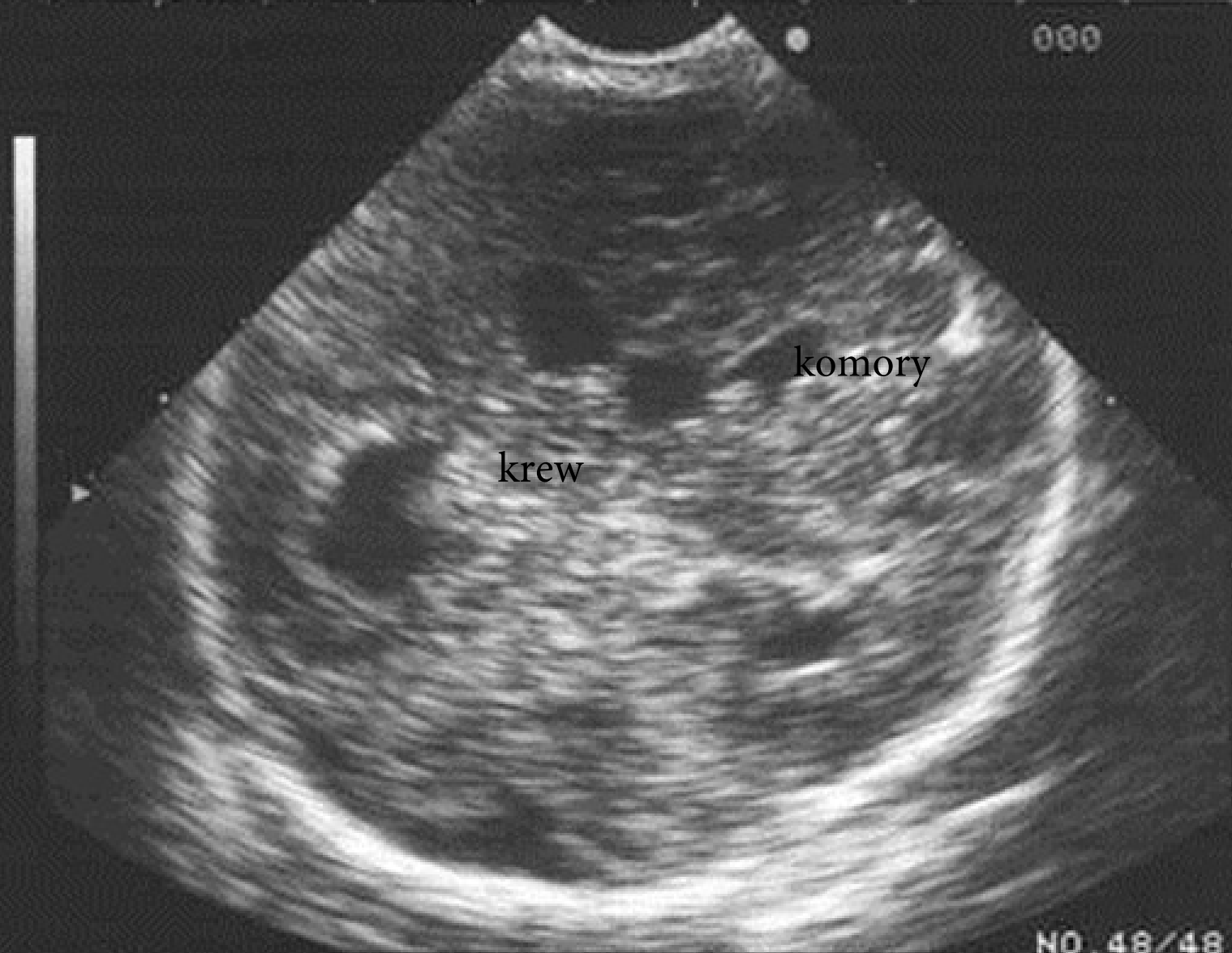


# Co możemy oglądać?

- **GŁOWA**
  - USG przezciemiączkowe
  - Ślinianki



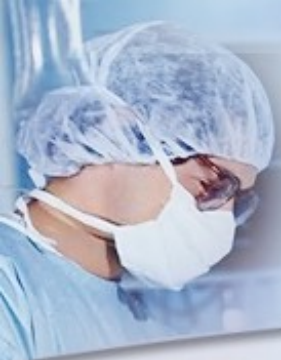000



ID: 0/F  
1999/08/05 F5  
10:41:28

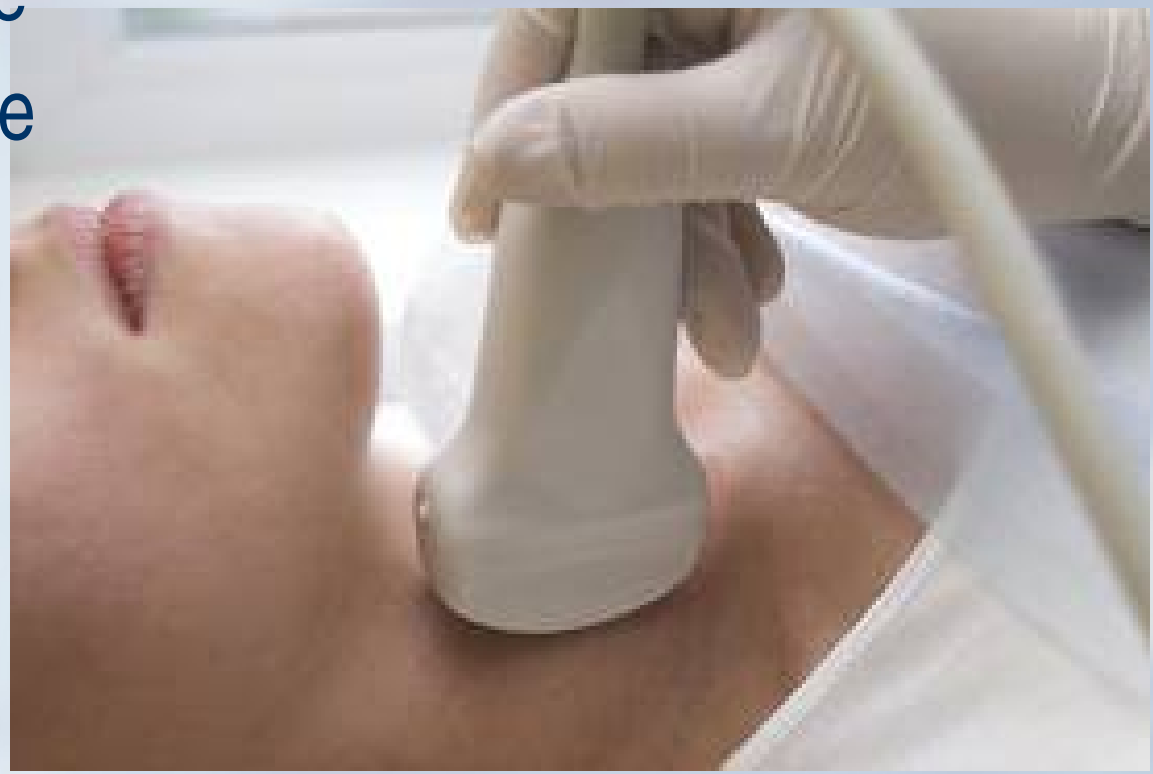PSK NR 3 AM W-MA, DZIAŁDÓWSKA 1

NO. 48/48



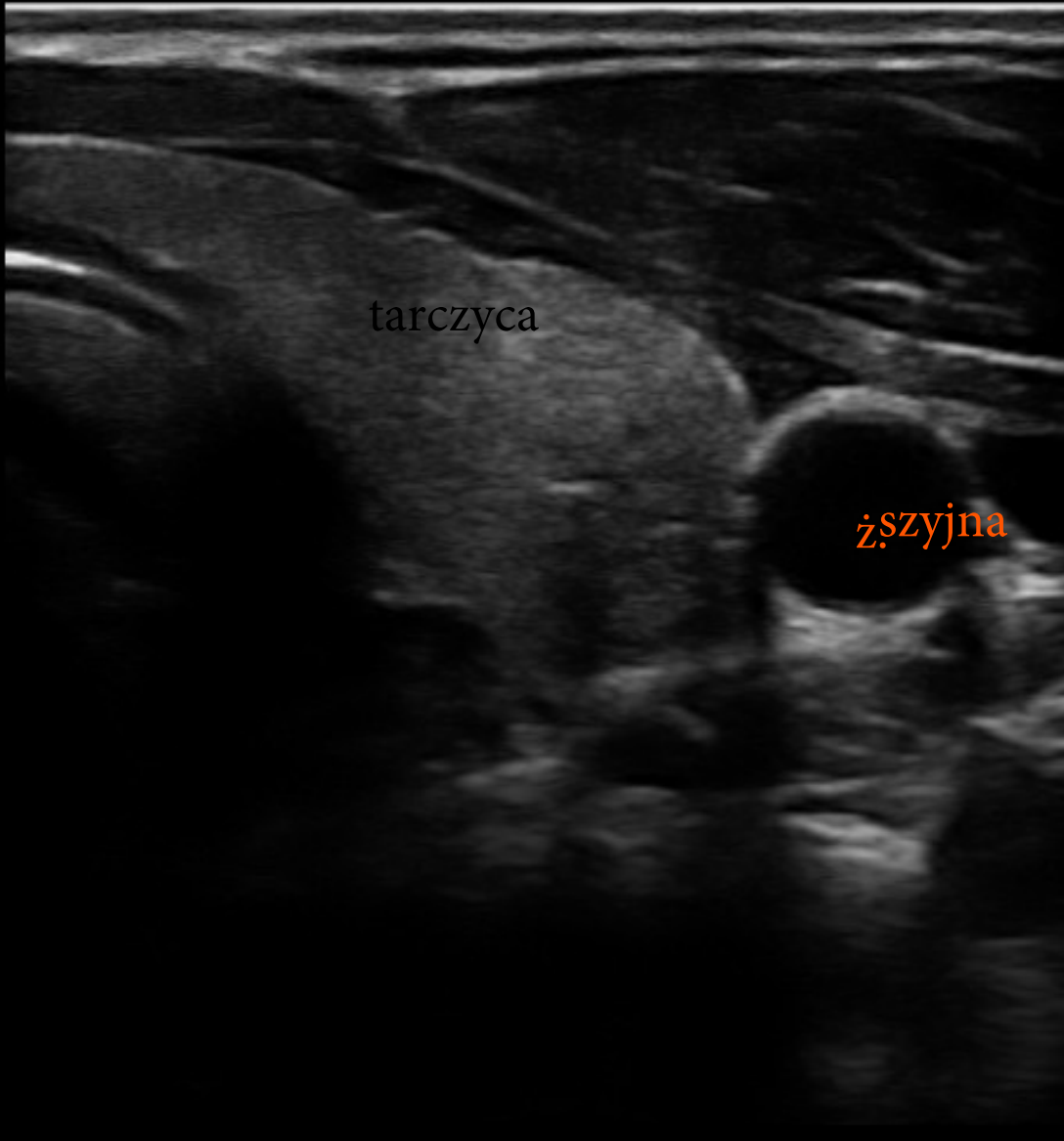## ■ SZYJA

- Tarczycyca
- Tętnice szyjne
- Węzły chłonne



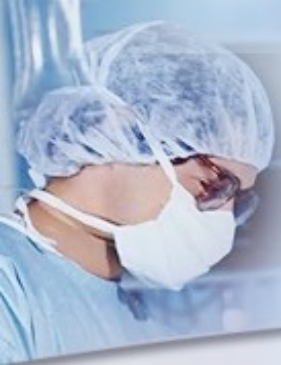

U

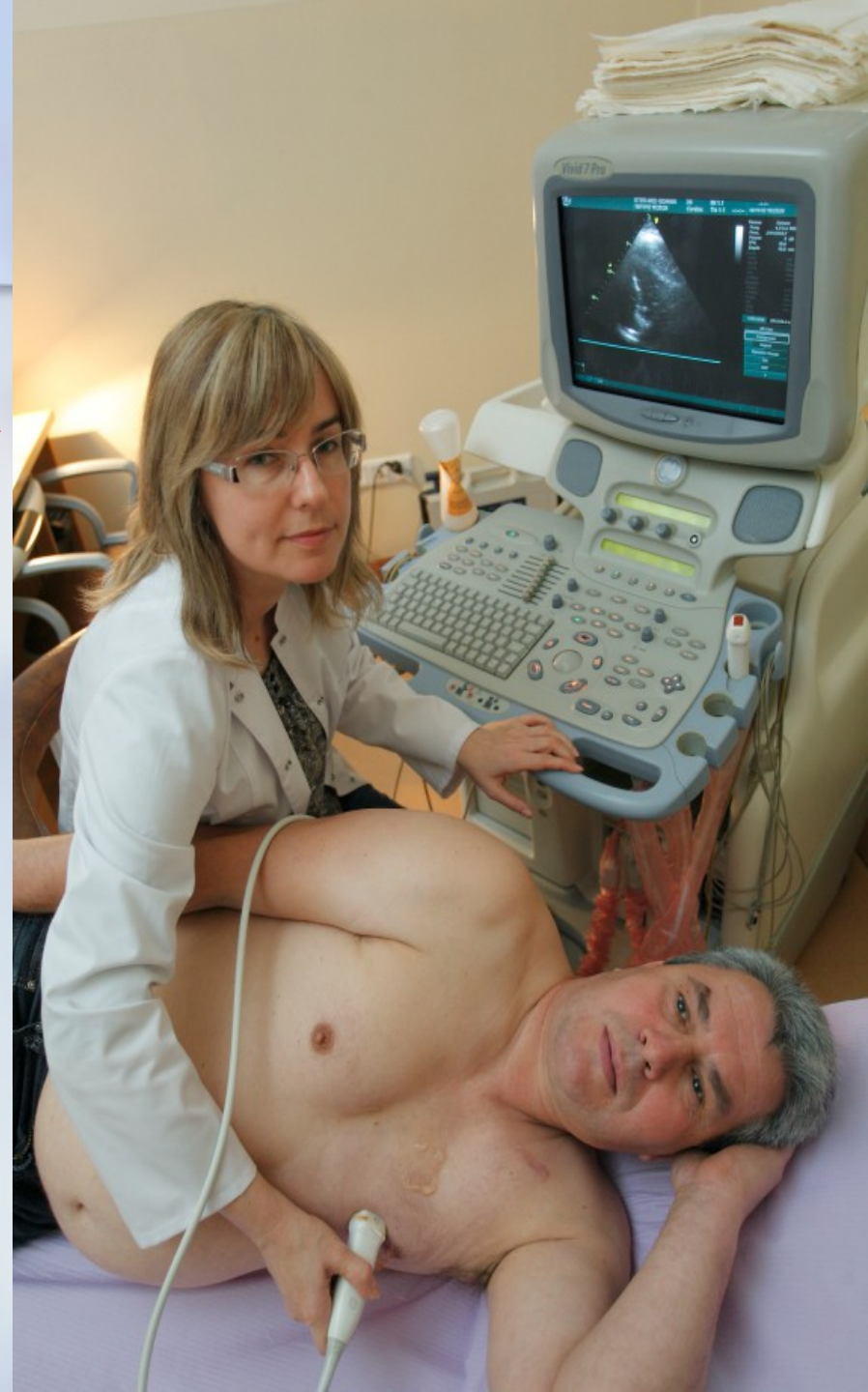

tarczyca

ższyjna



- **KLATKA PIERSIOWA**
- Gruczoł piersiowy
- Serce





U

komora p

przedsionek p

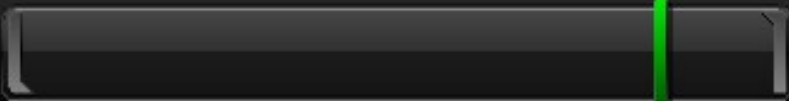
462

-

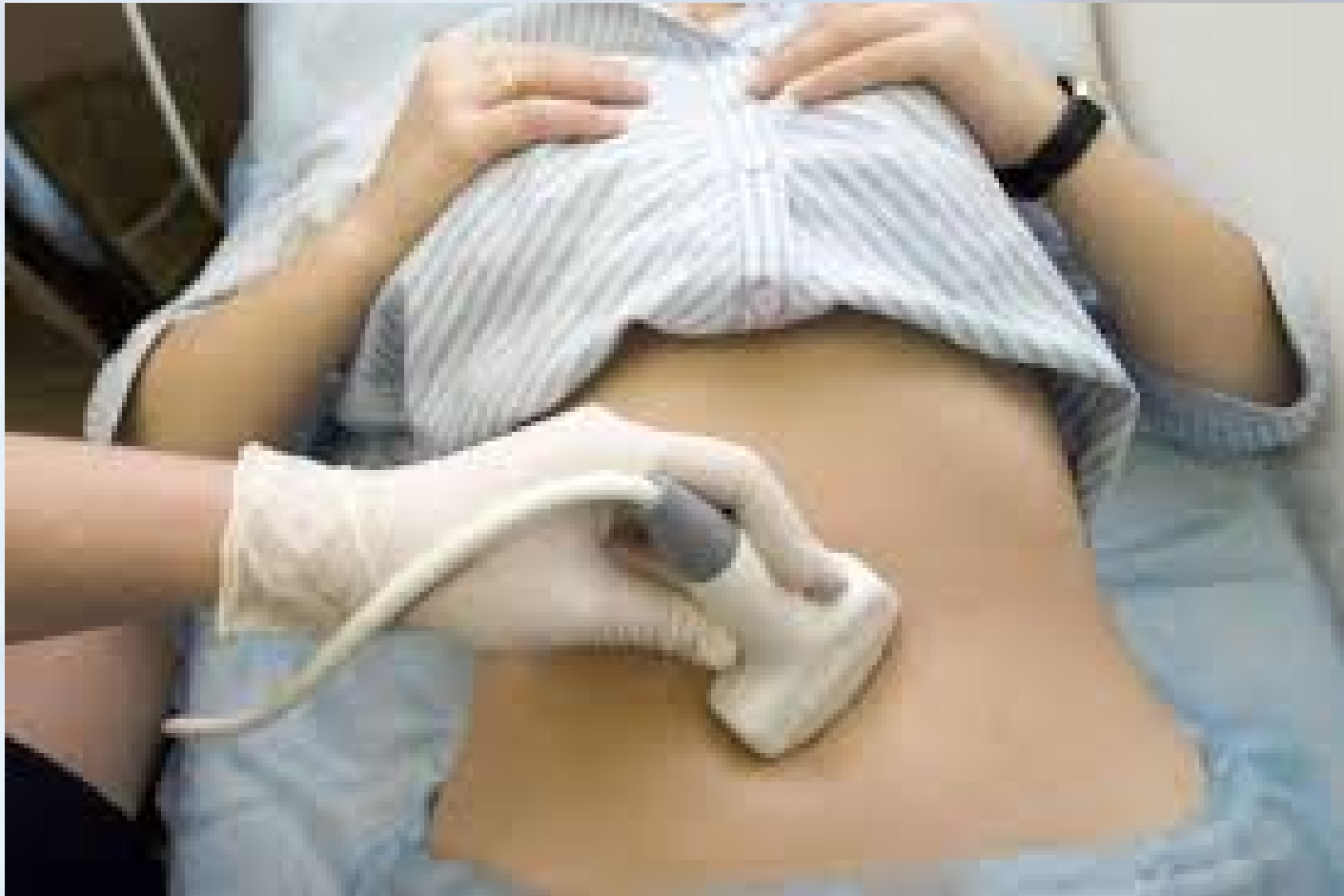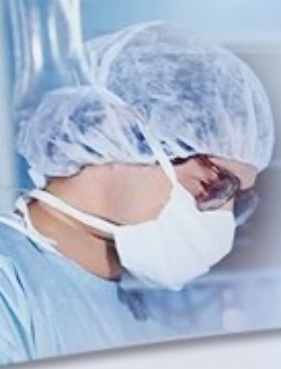+

x 1

B

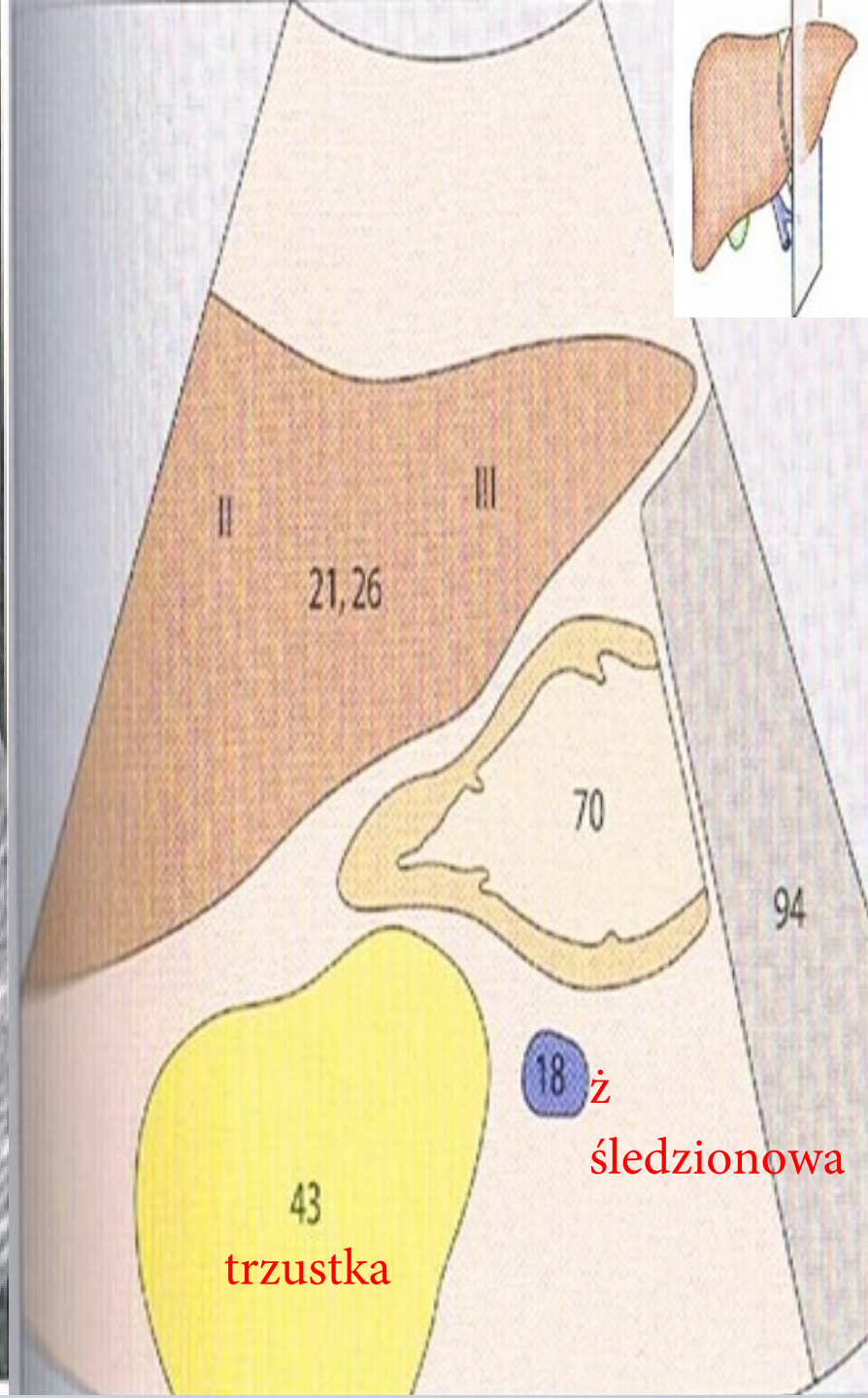
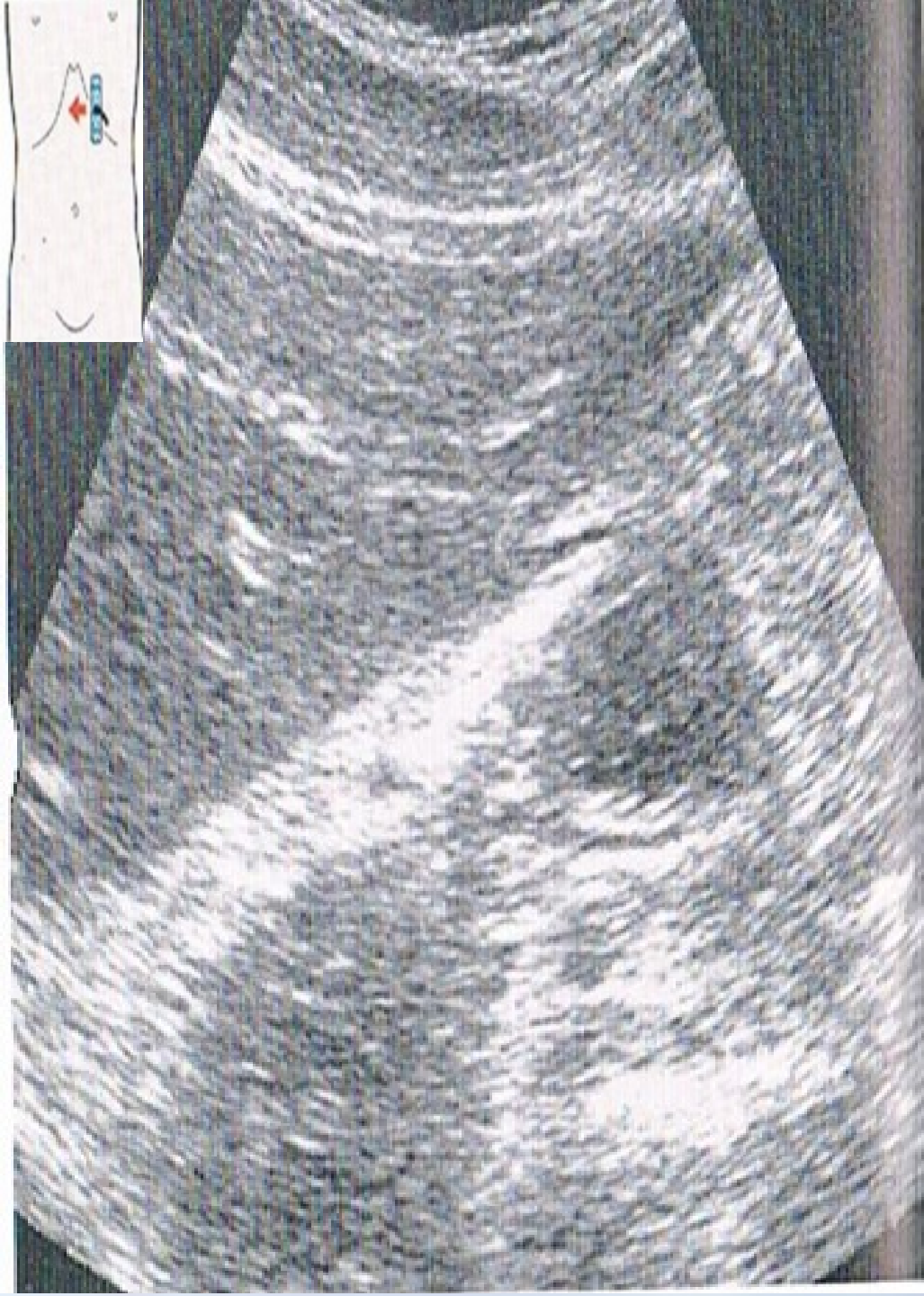

# JAMA BRZUSZNA I MIEDNICA

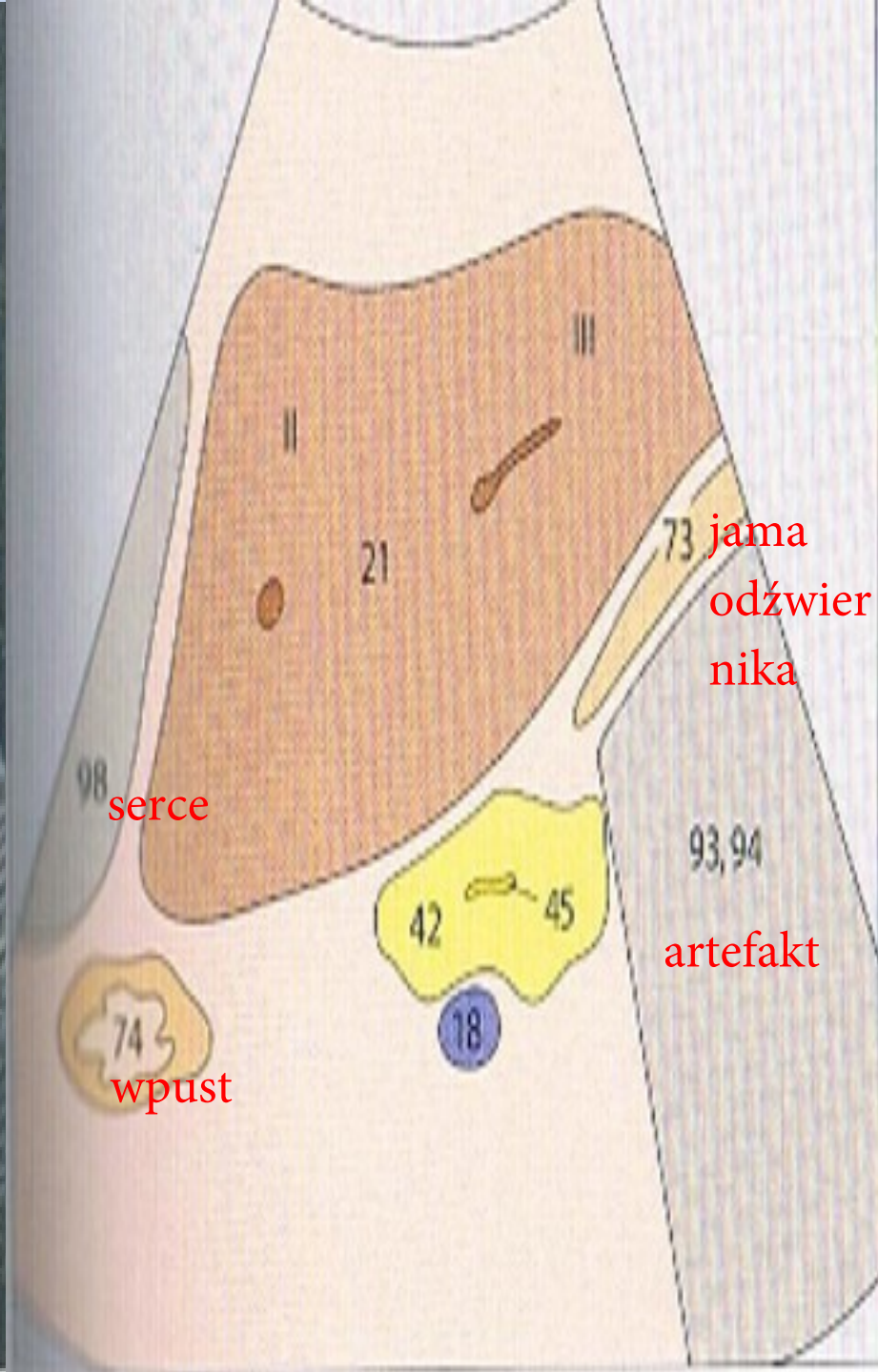
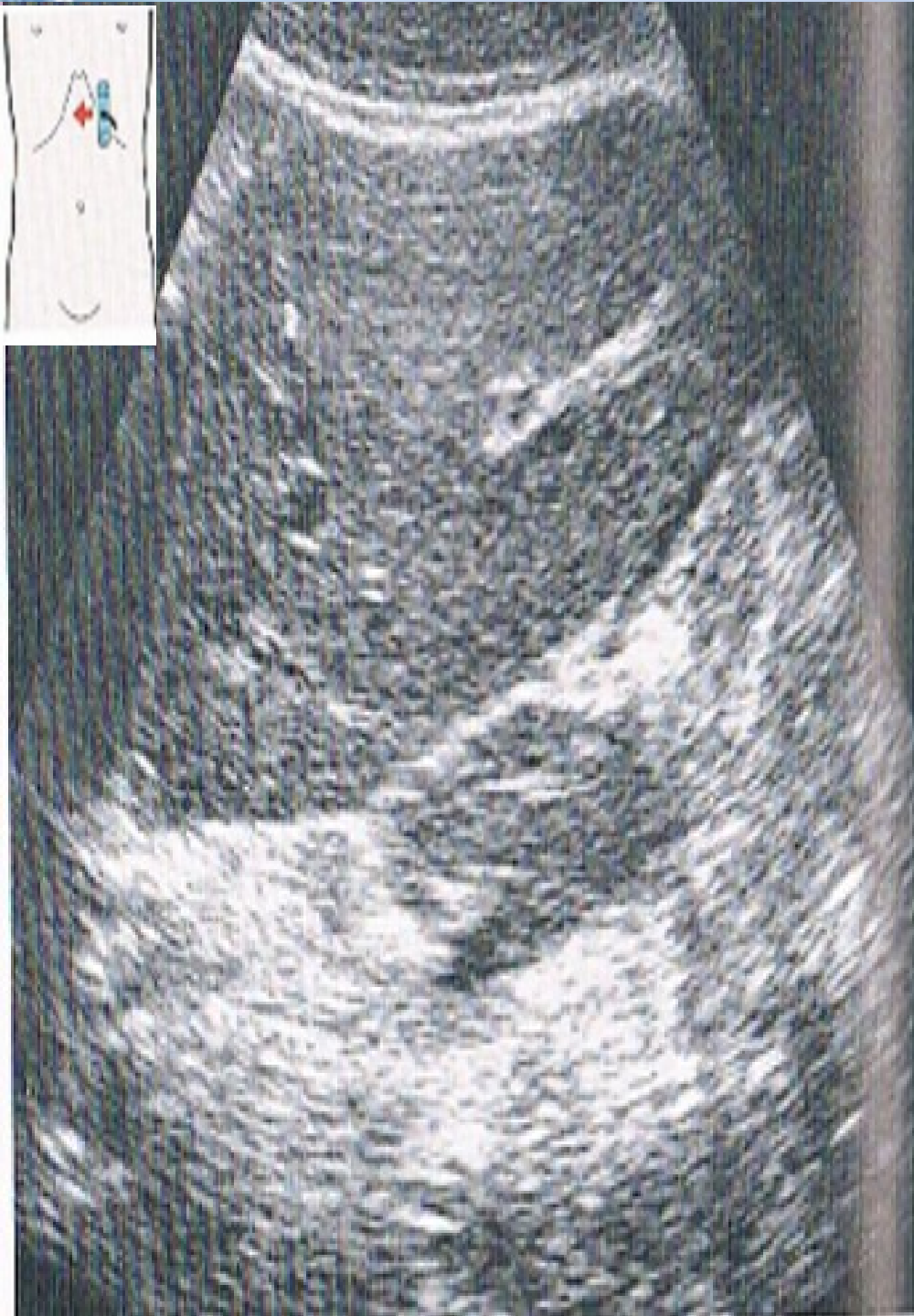


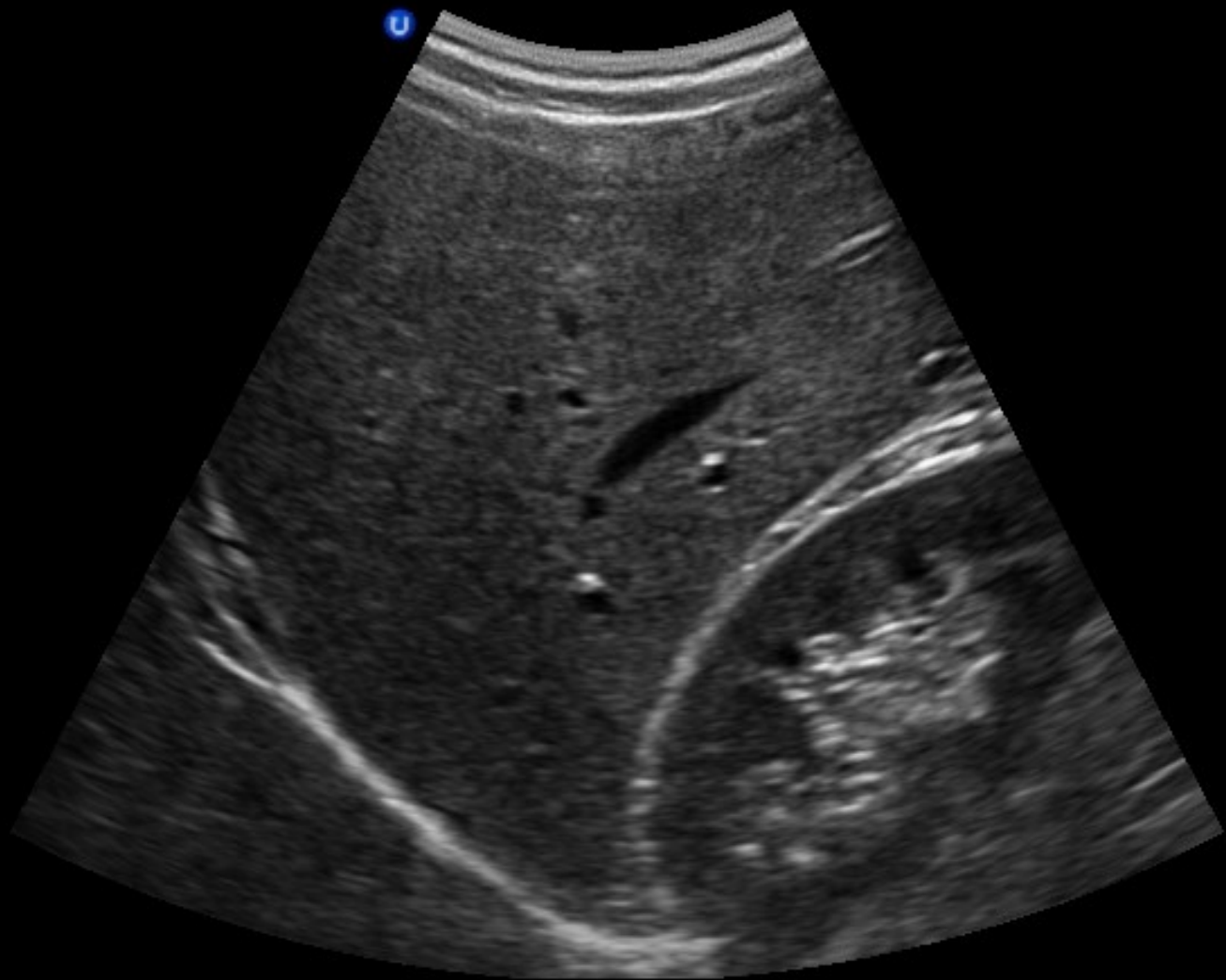

# ■ WĄTROBA





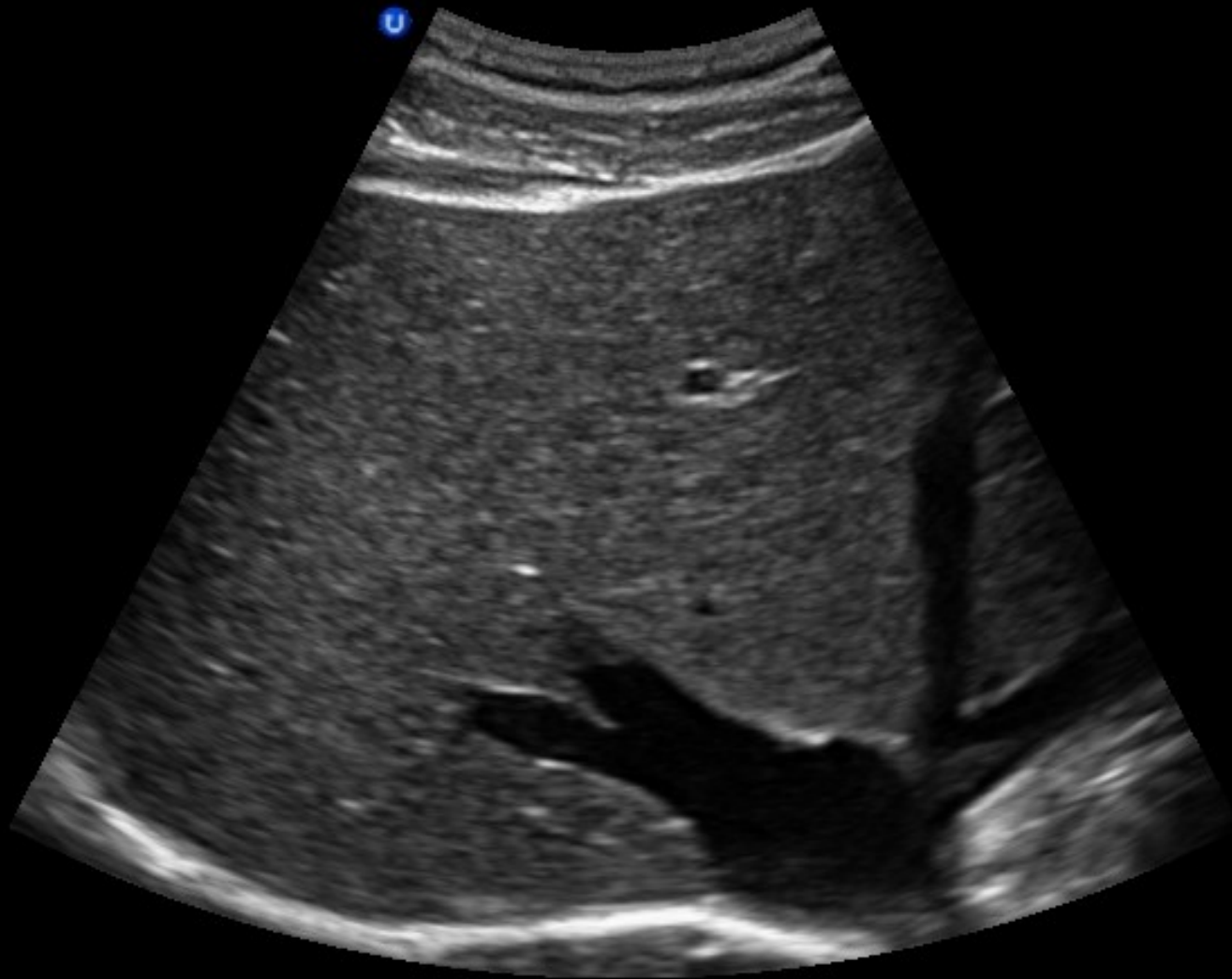




LIVER - RENAL ECHOGENCITY



ULTRASONIX



TRANSVERSE HEPATIC VEINS



9194-06-06-03-1

RAB 2-5L/Abdomen

MI 1.3

www.ULTRAMEDICA.pl - 4D 3D

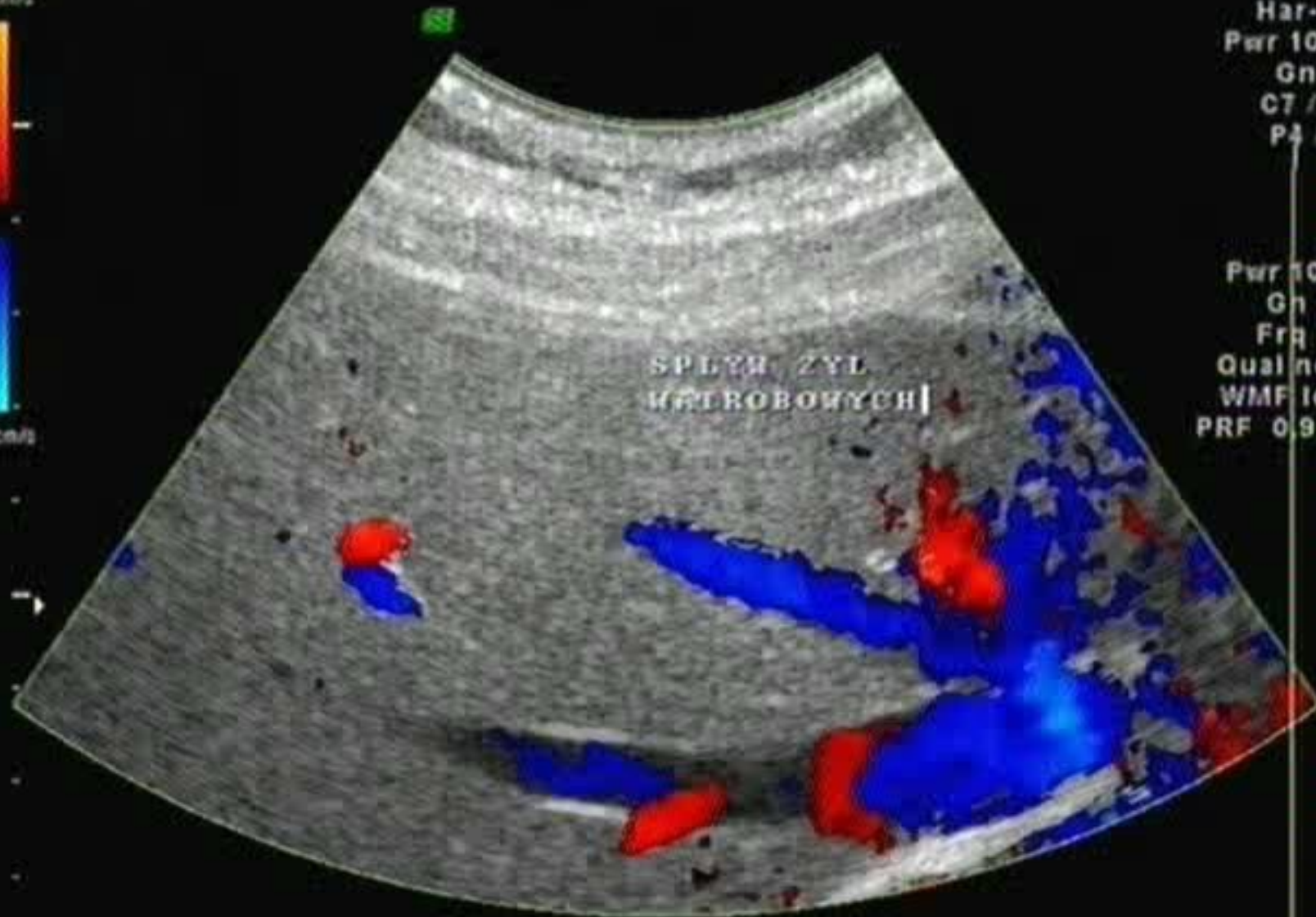8.5cm / 6Hz

03-06-2006 12:25:18

13cm/s



-13cm/s

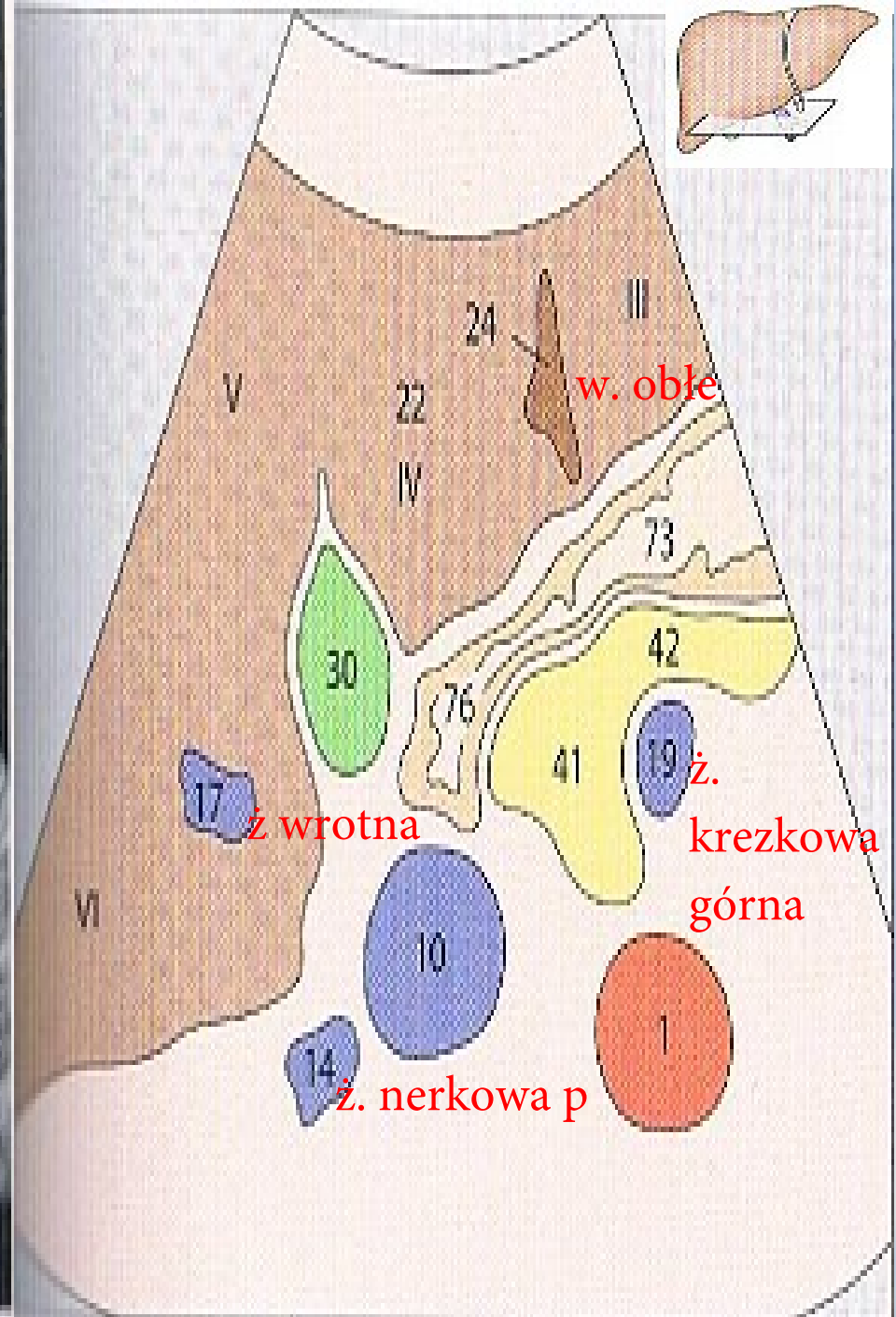
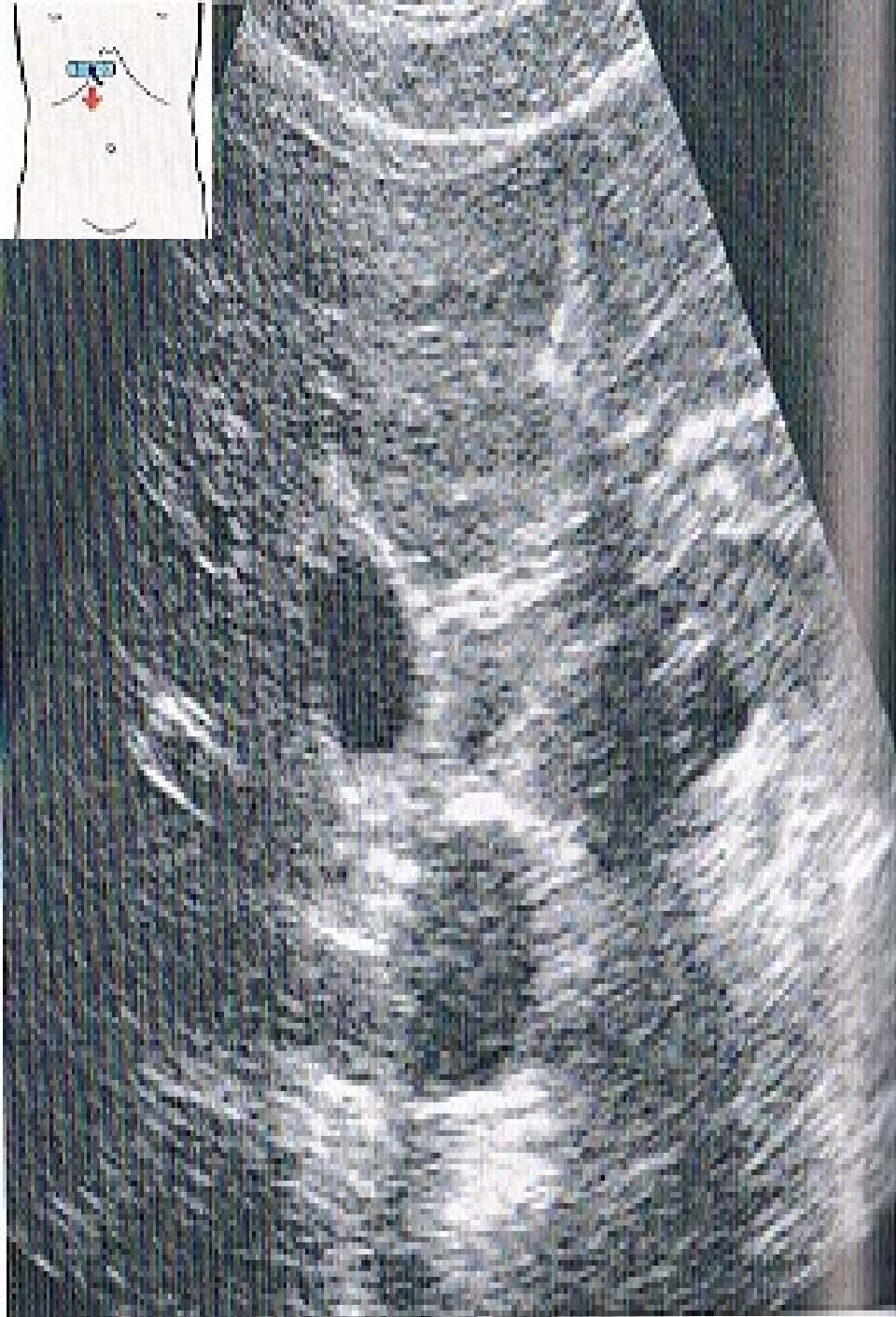

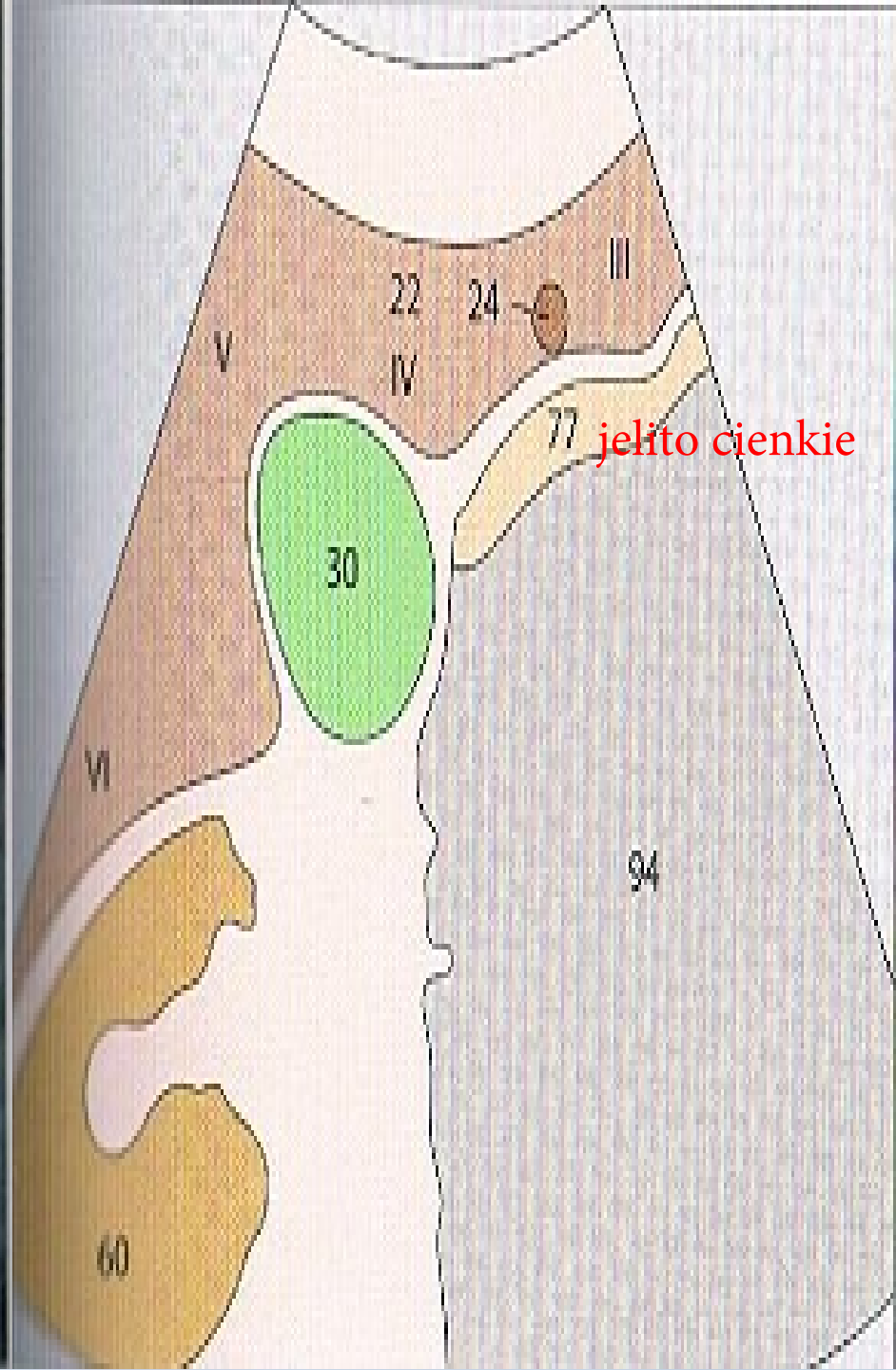
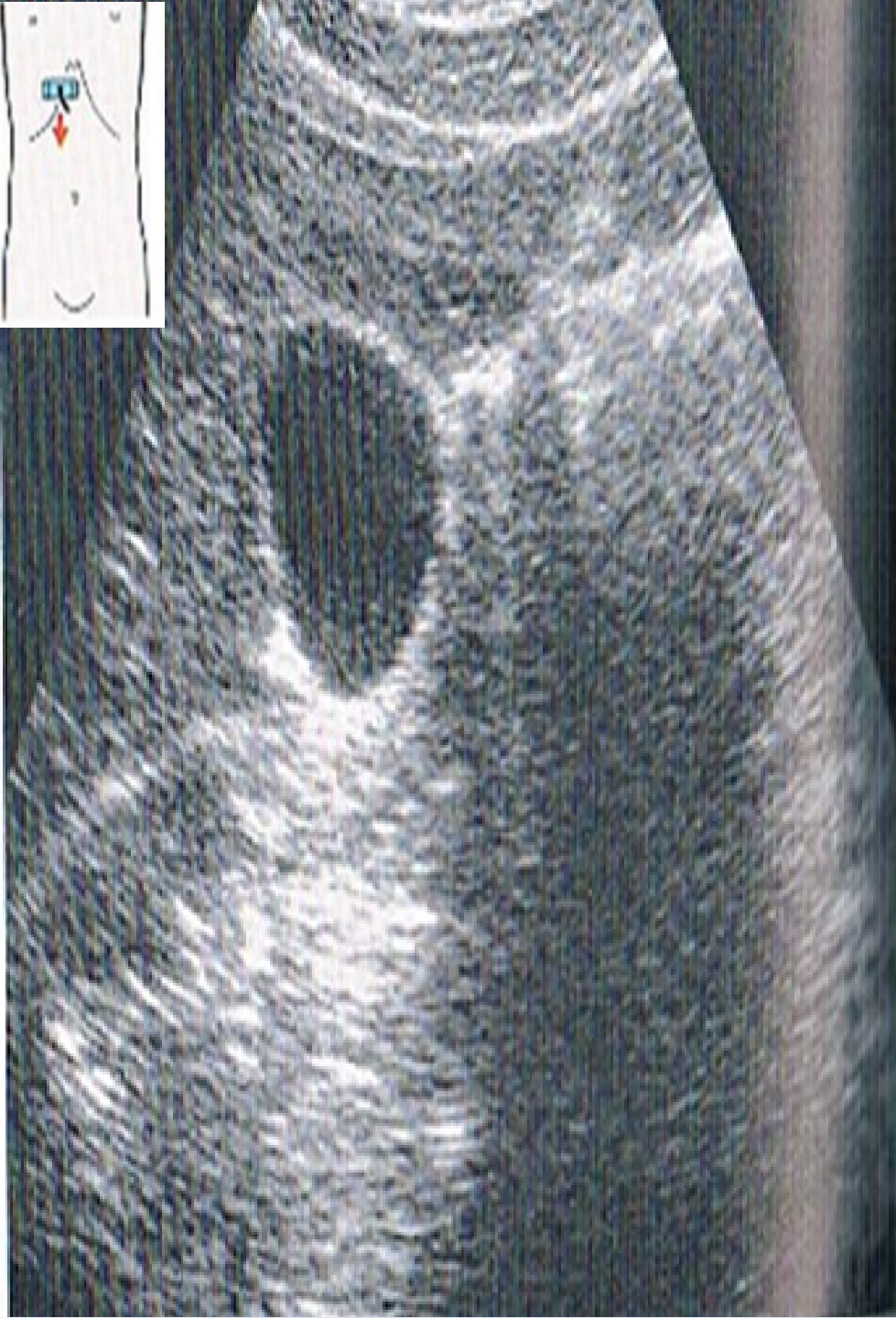
Kidney  
Har-low  
Pwr 100 %  
Gn 15  
C7 / M4  
P4 / E1

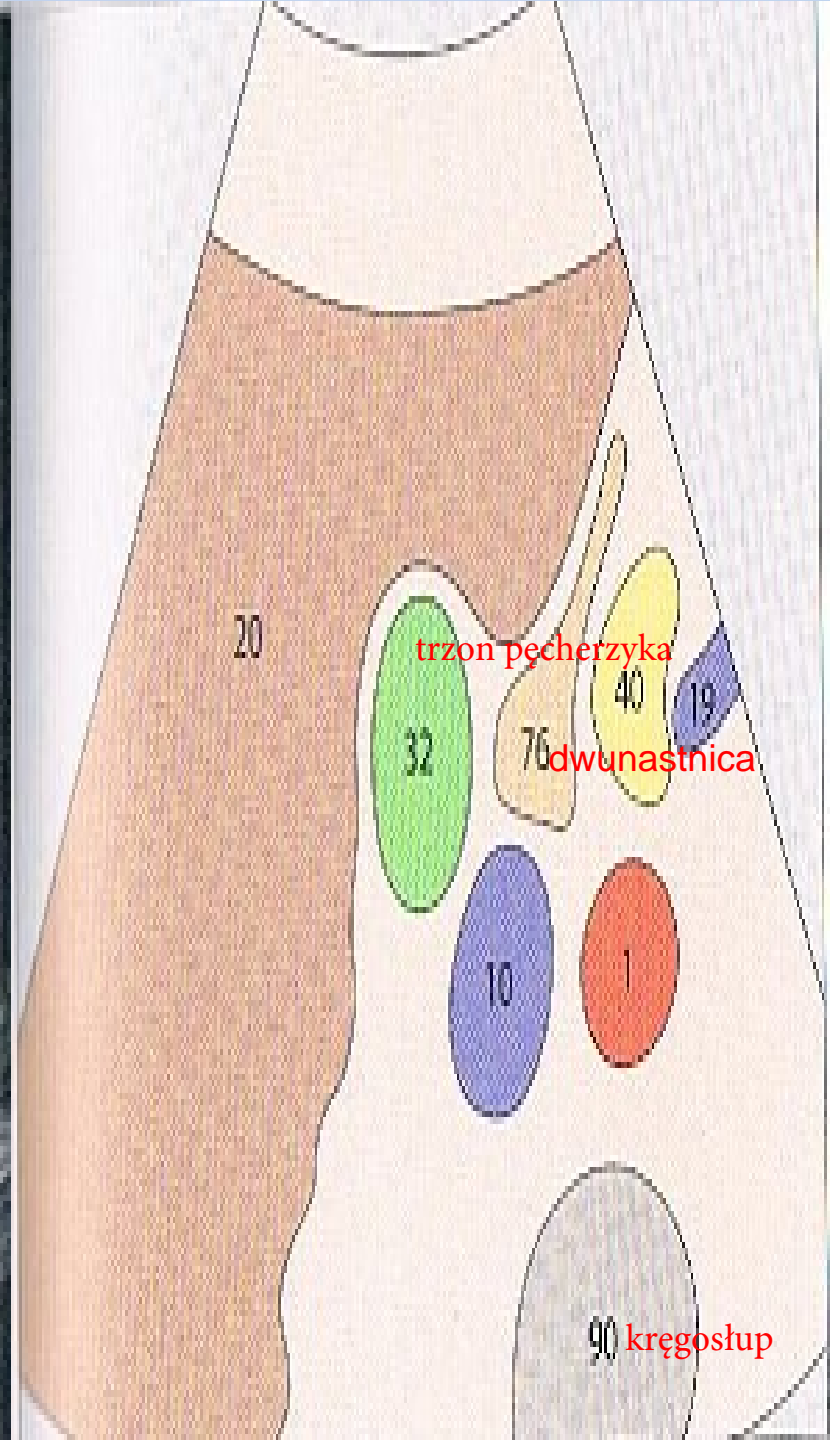
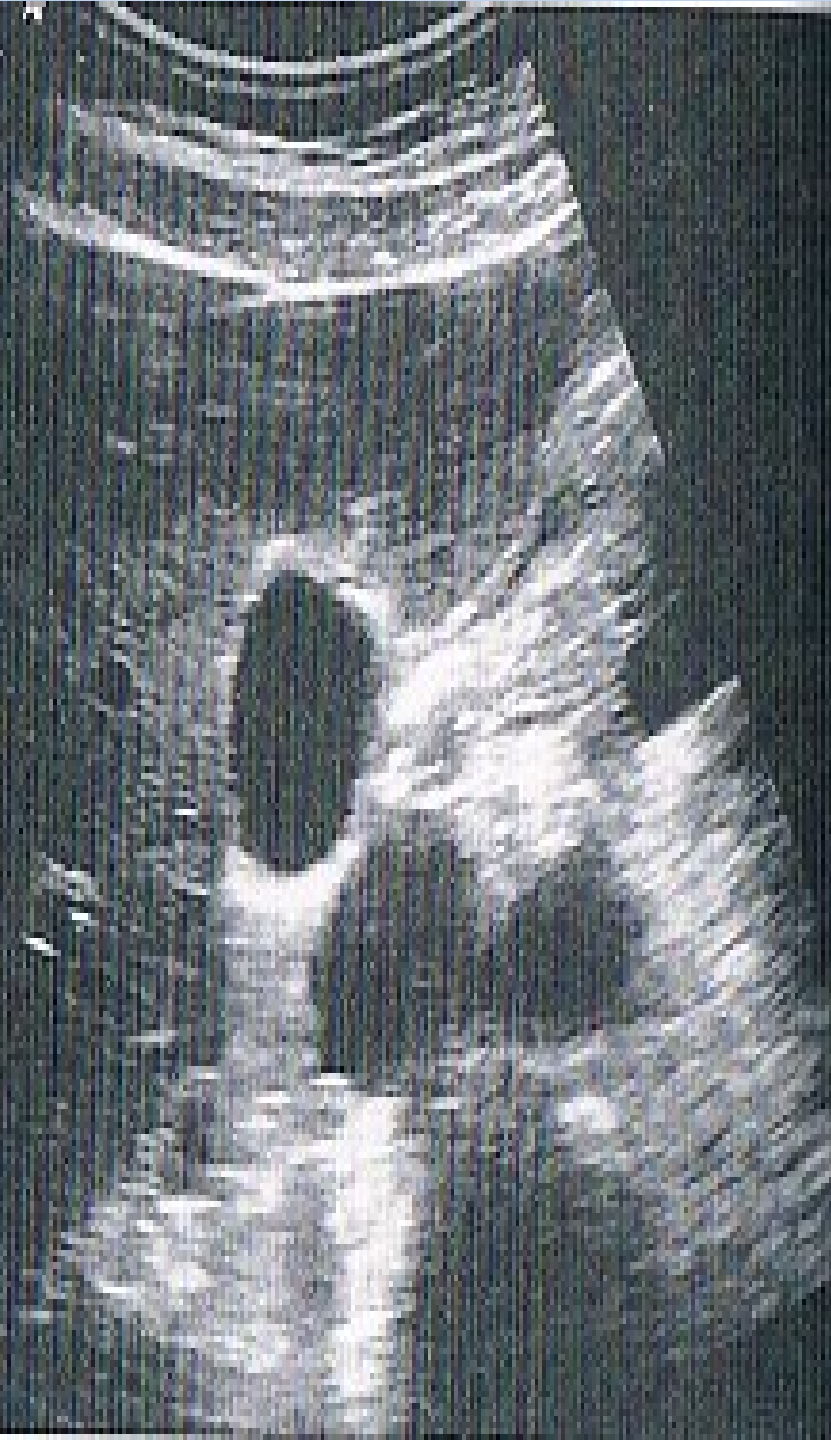Pwr 100 %  
Gn 1.0  
Frg mid  
Qual norm  
WMF low1  
PRF 0.9kHz



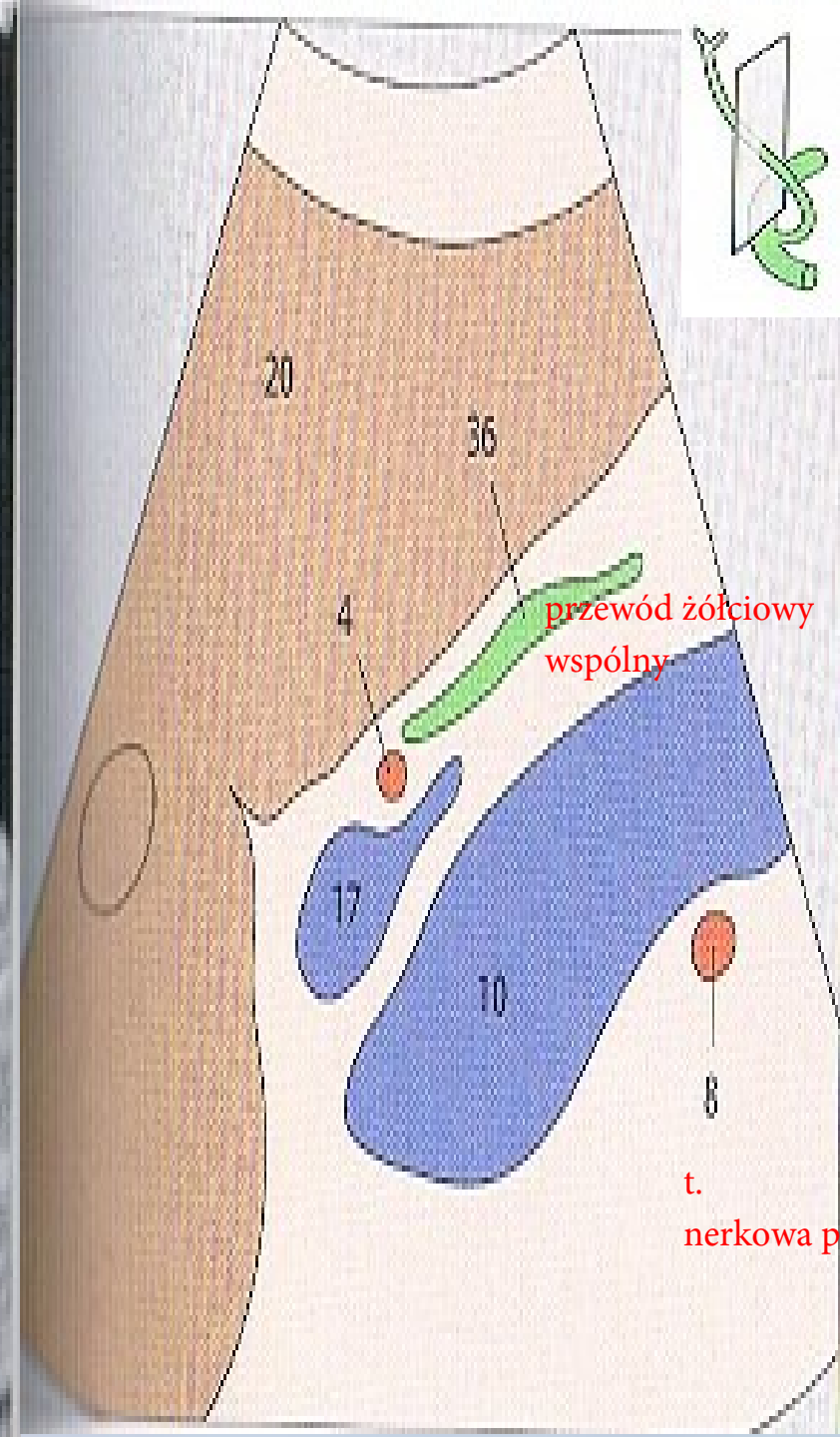

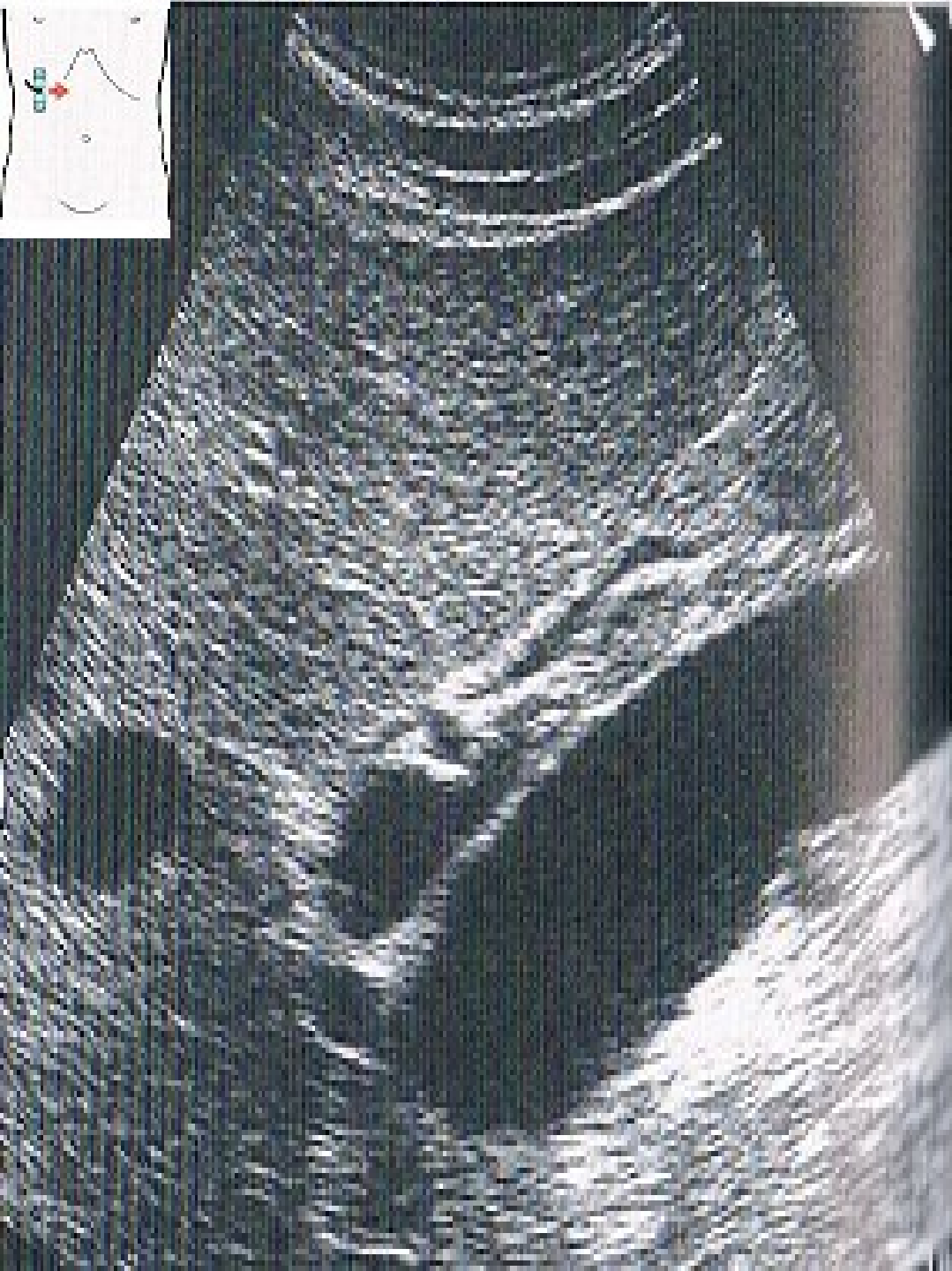
- Pęcherzyk żółciowy, drogi żółciowe

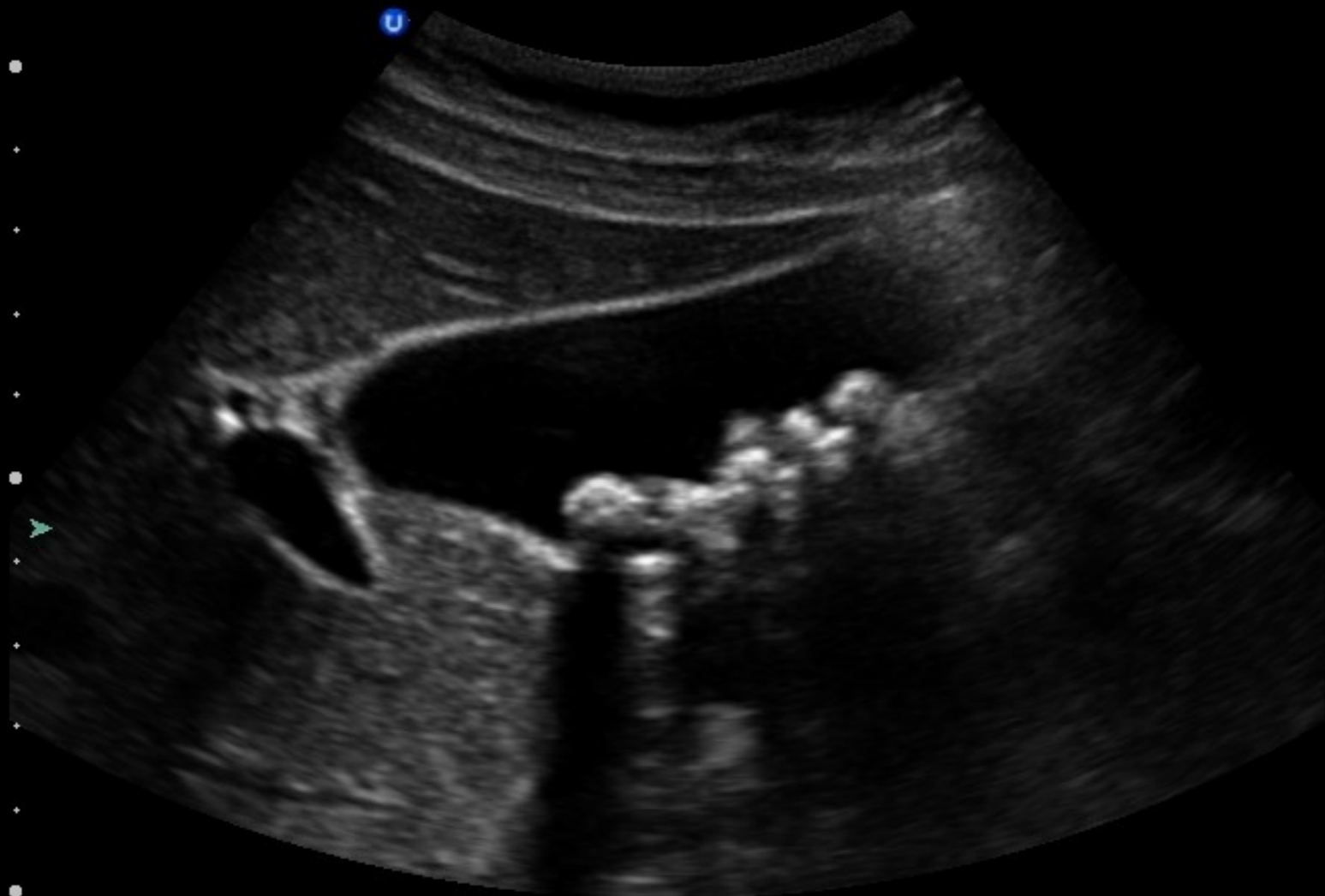









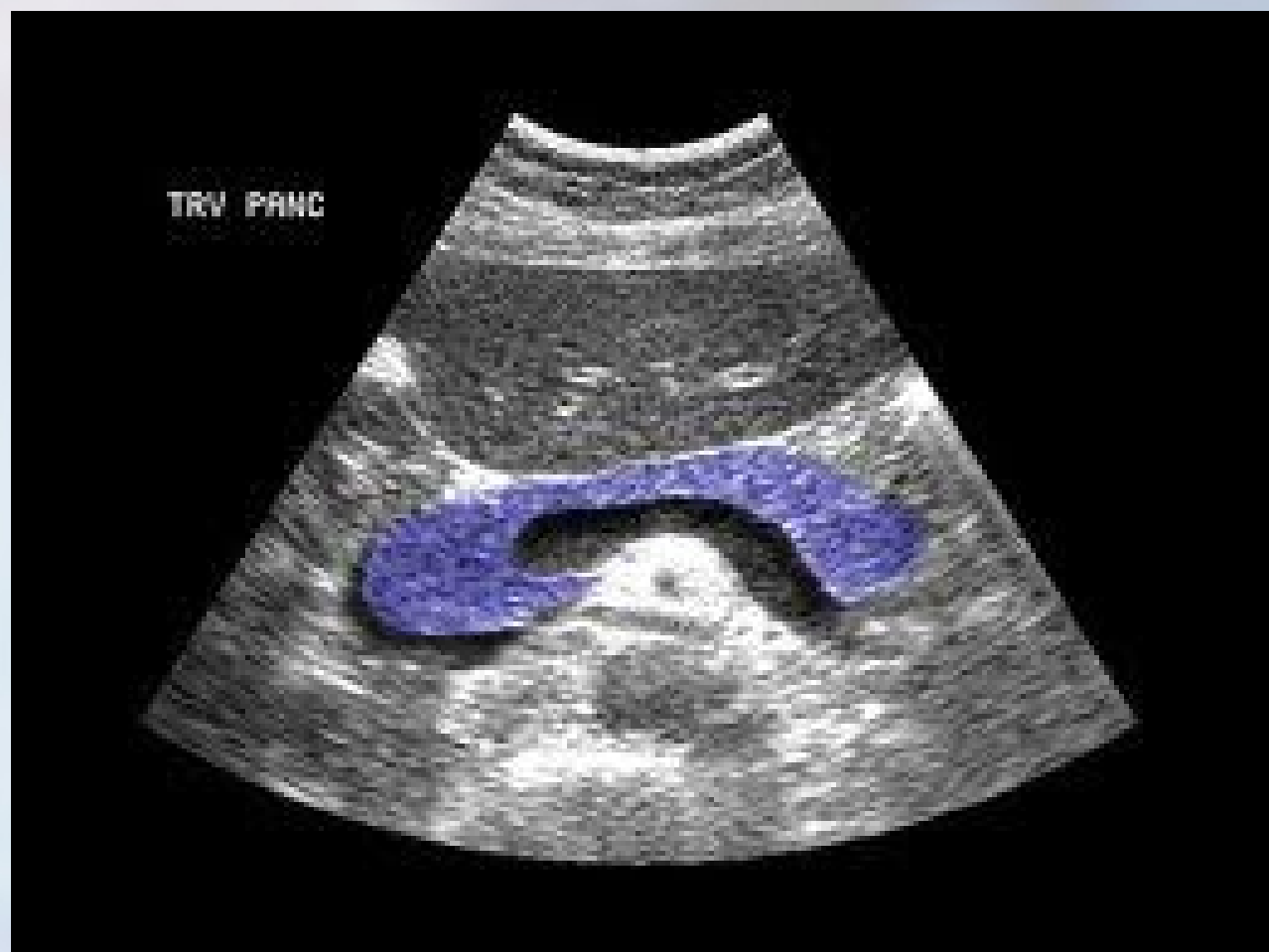

GALLSTONES



## ■ Trzustka





9194-06-06-03-1

RAB 2-5L/Abdomen

MI 1.1

www.ULTRAMEDICA.pl - 4D 3D

11.9cm / 44Hz

03-06-2006 12:14:21

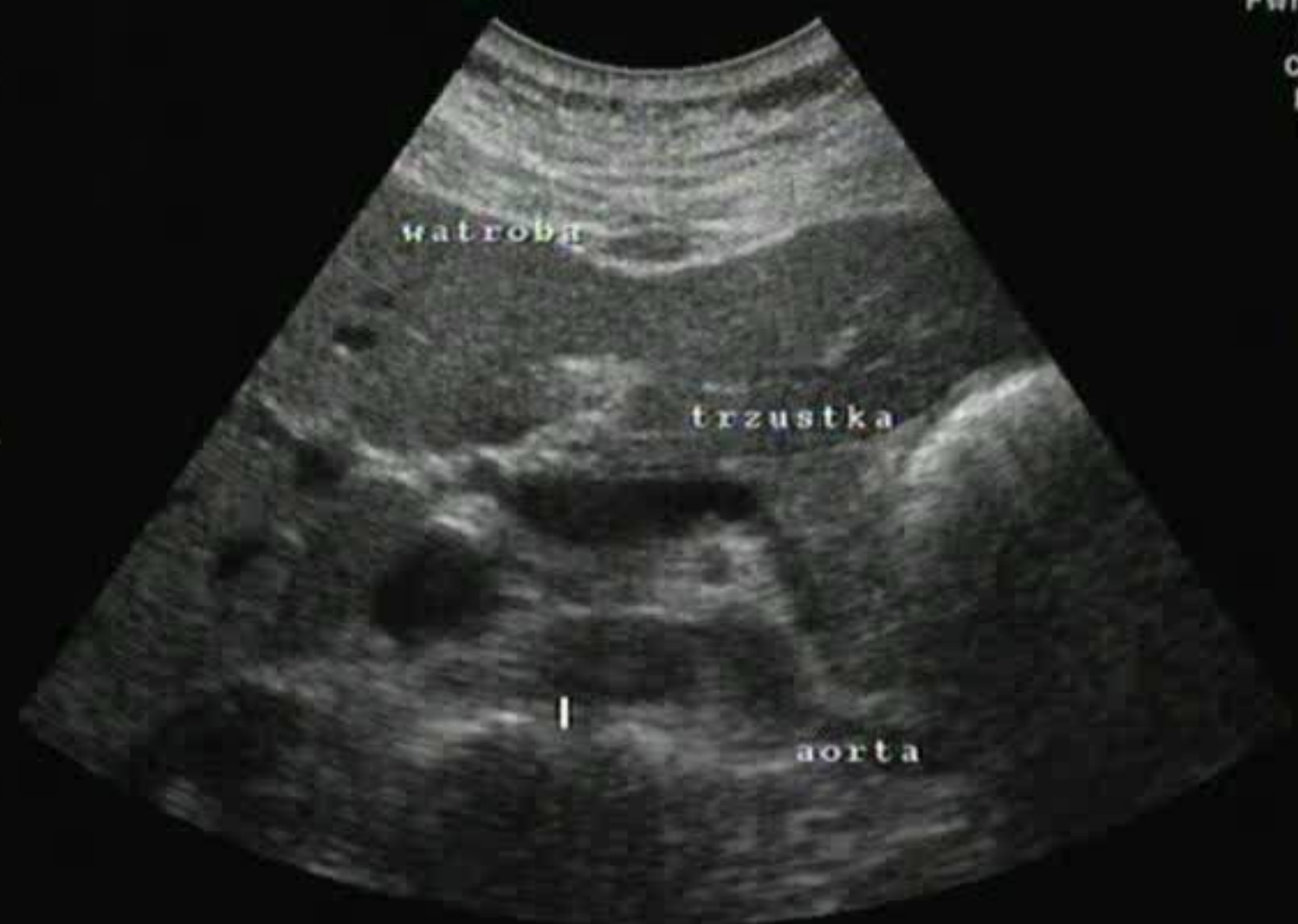
Kidney  
Har-low  
Pwr 100 %  
Gn 5  
C7 / M4  
P4 / E1

67

watrob

trzustka

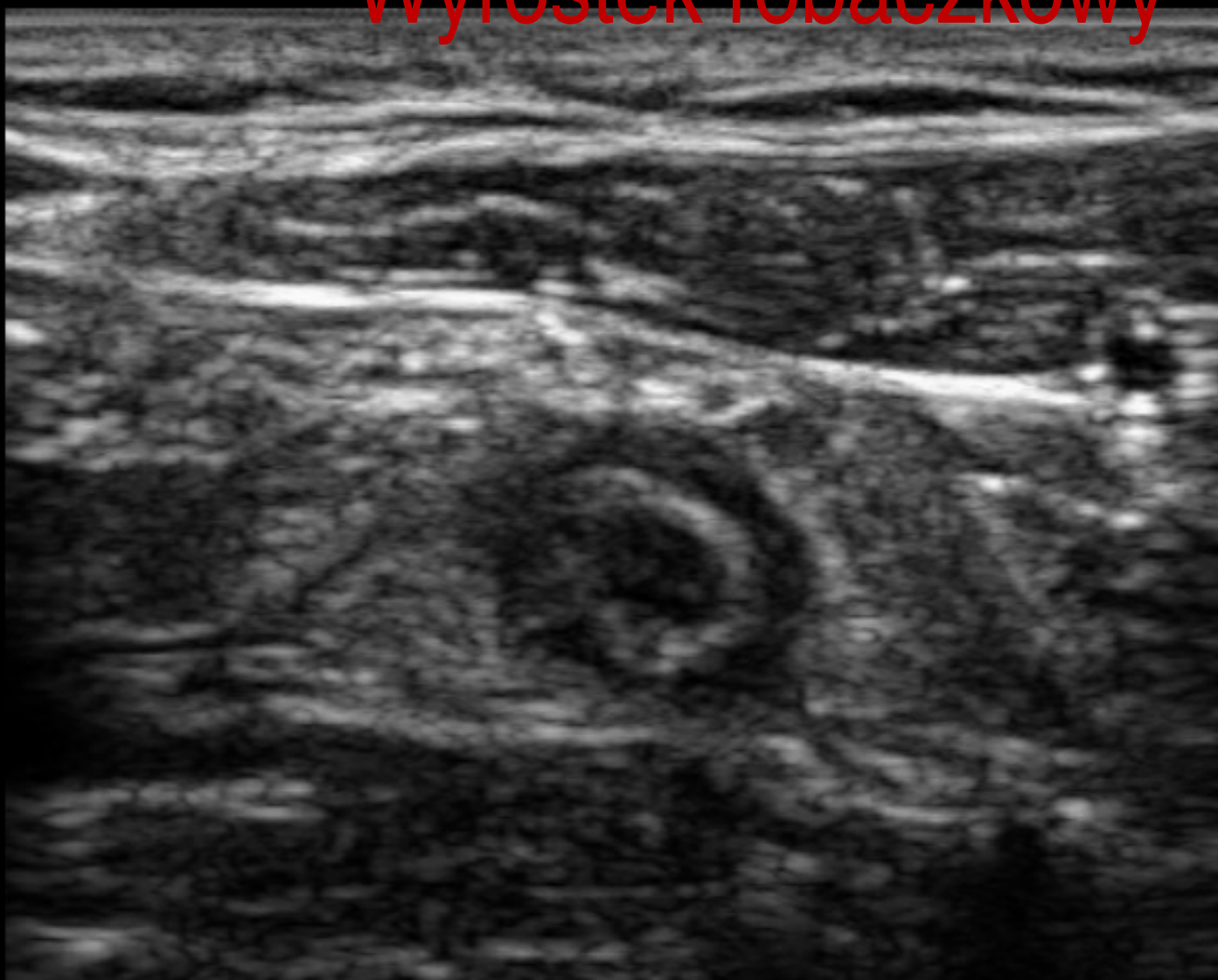
aorta





ULTRASONIX

# Wyrostek robaczkowy

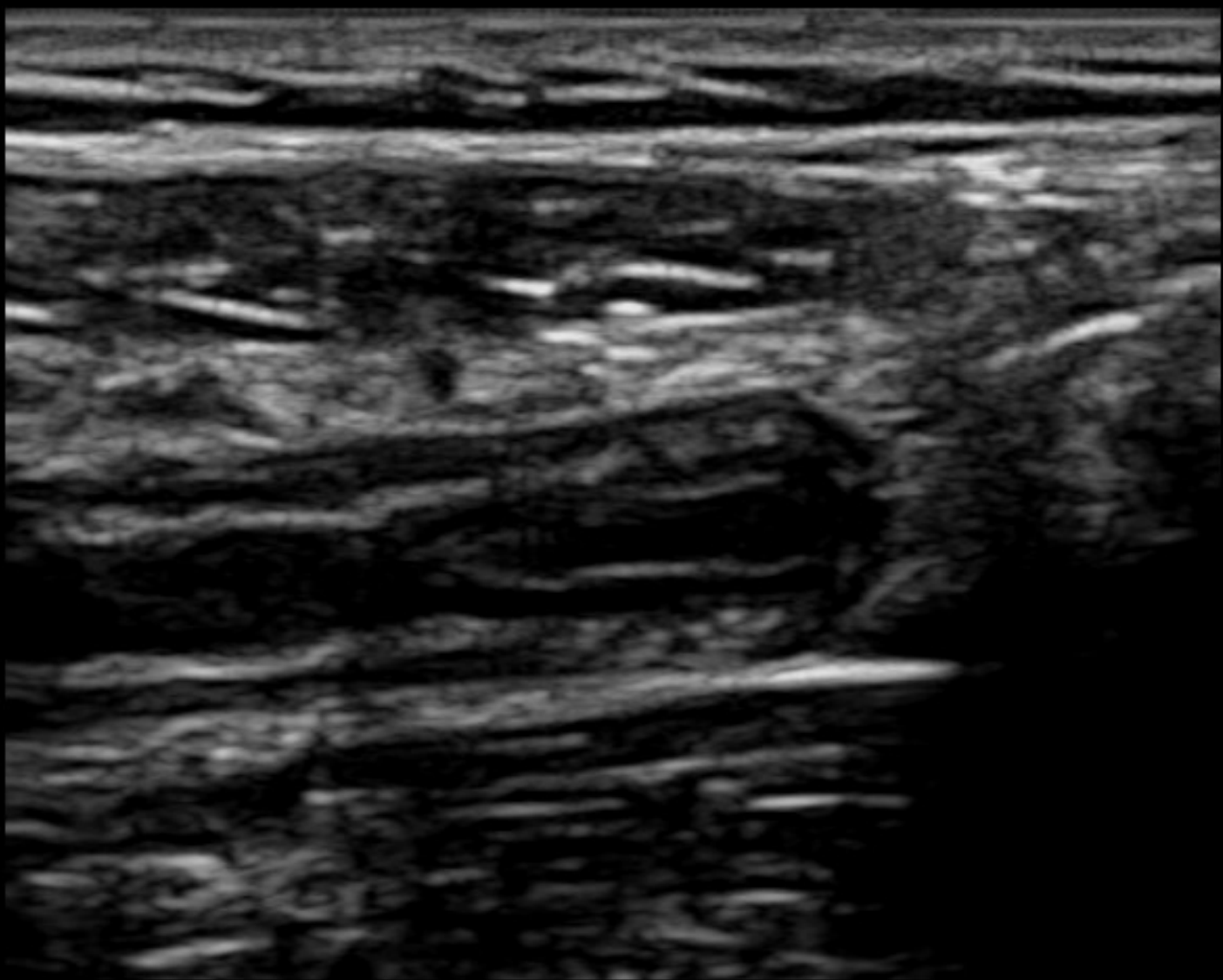


APPENDIX



ULTRASONIX

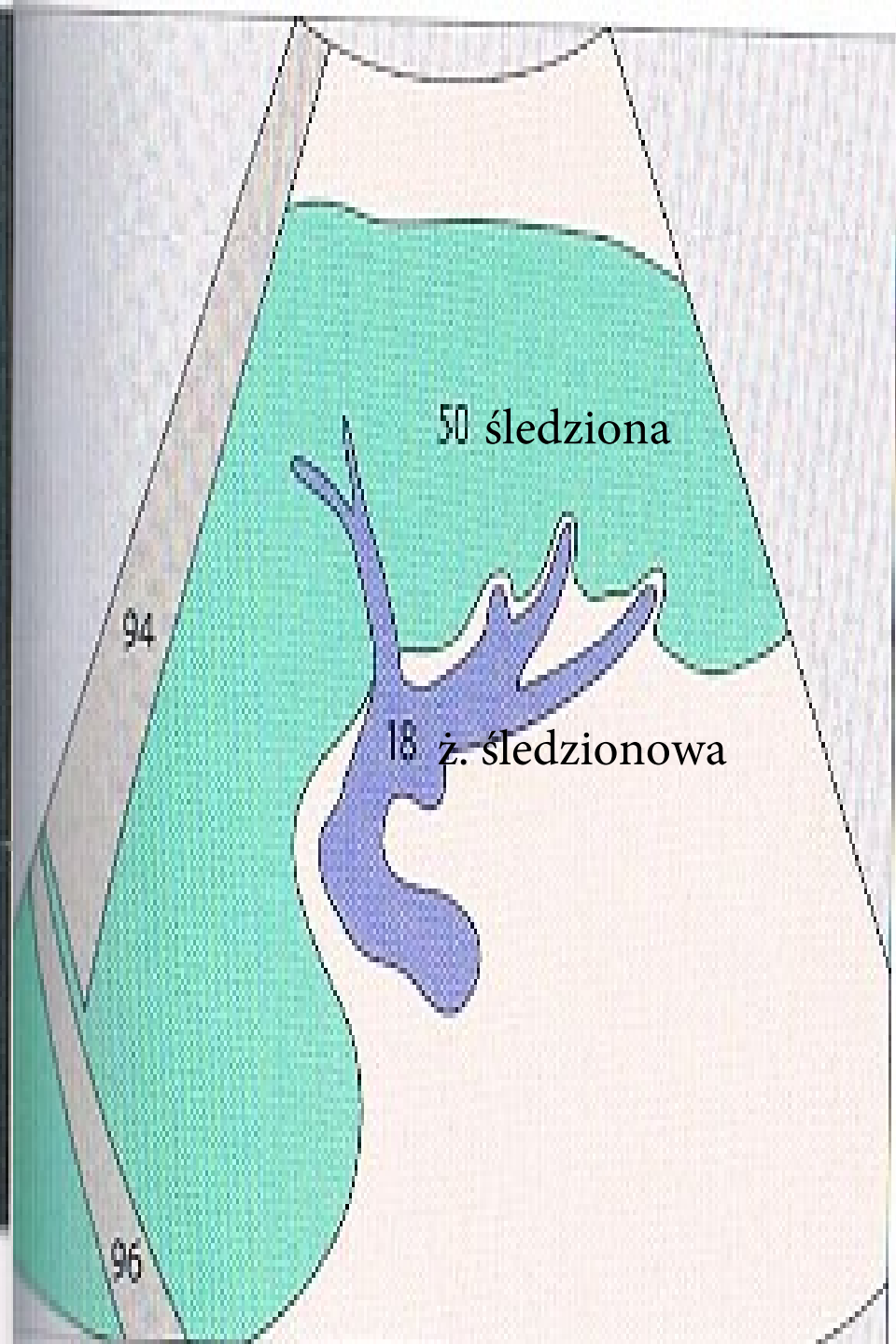
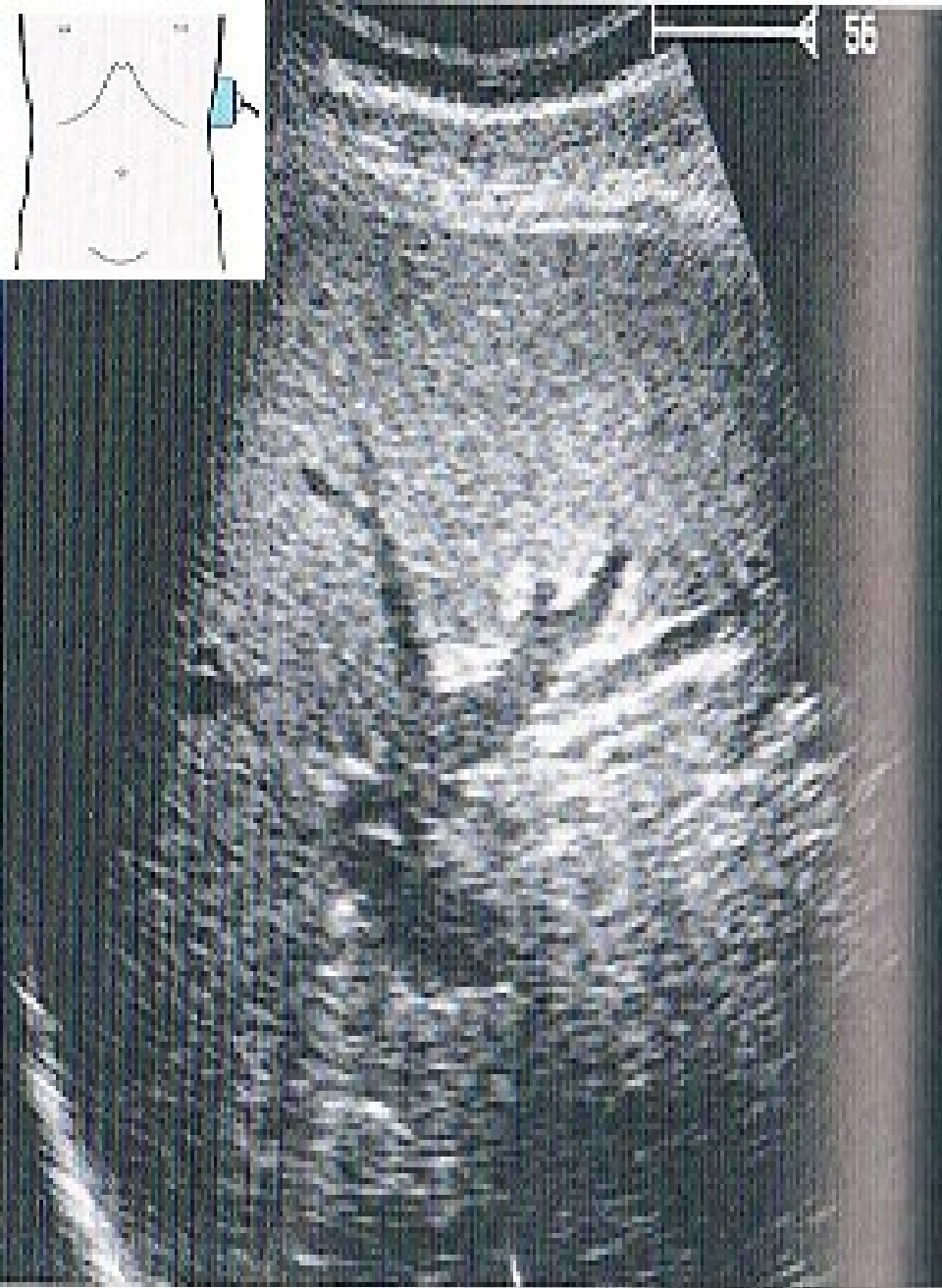
U



APPENDIX



# ■ ŚLEDZIONA

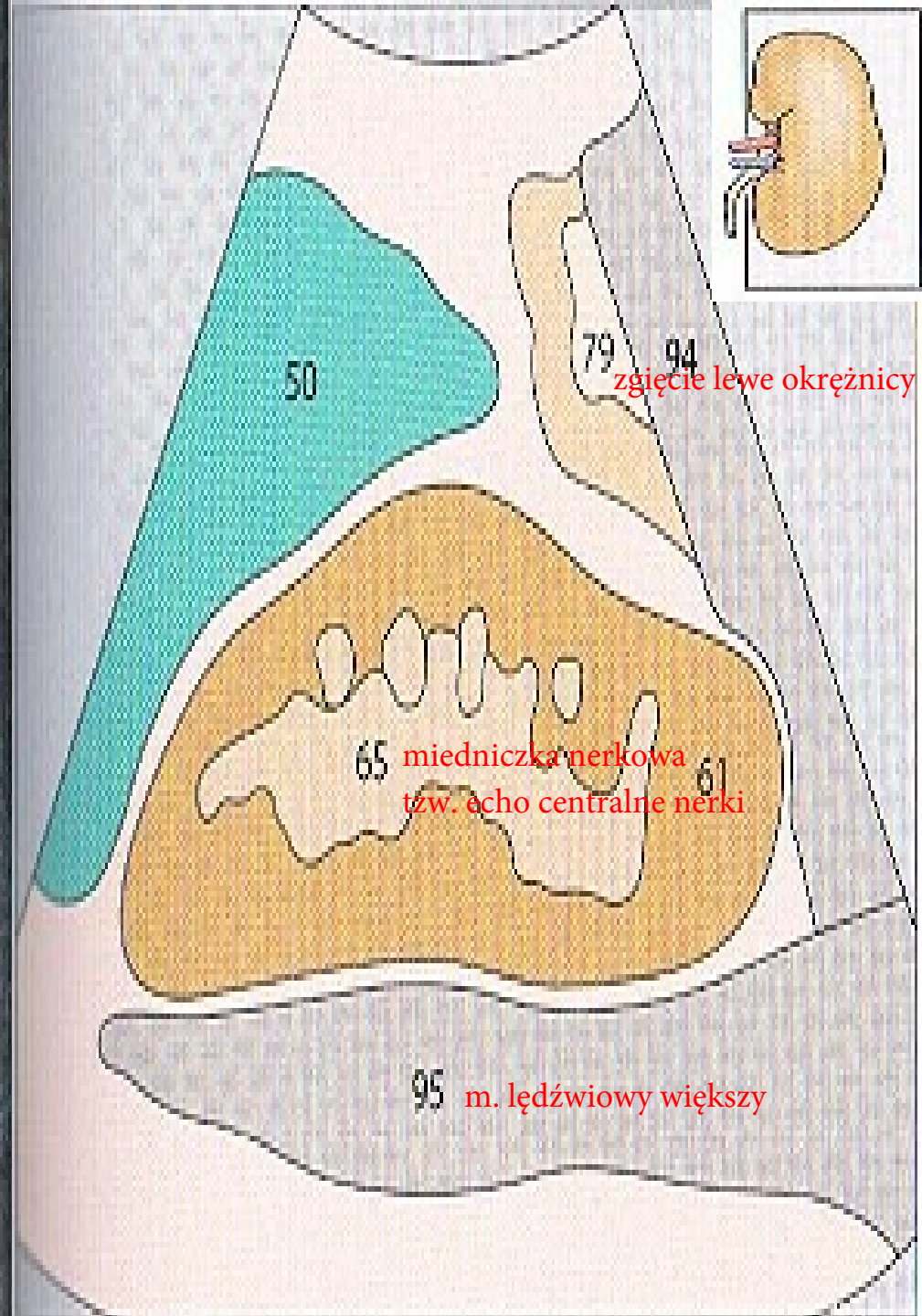
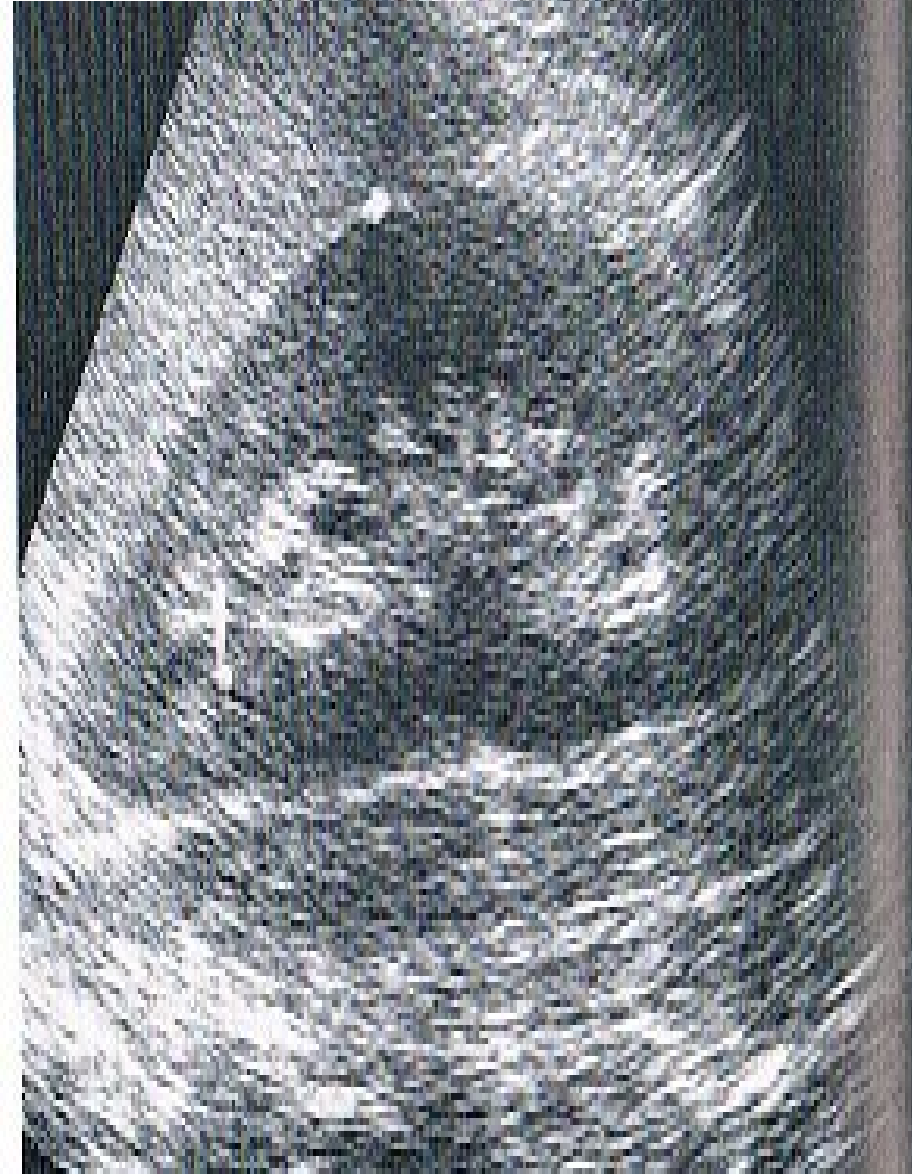
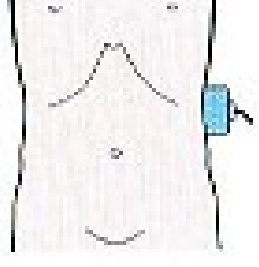


166 Wnęka śledziony, żyła śledzionowa





# ■ Nerka i nadnercze



50

79 94

zgięcie lewej okężnicy

65

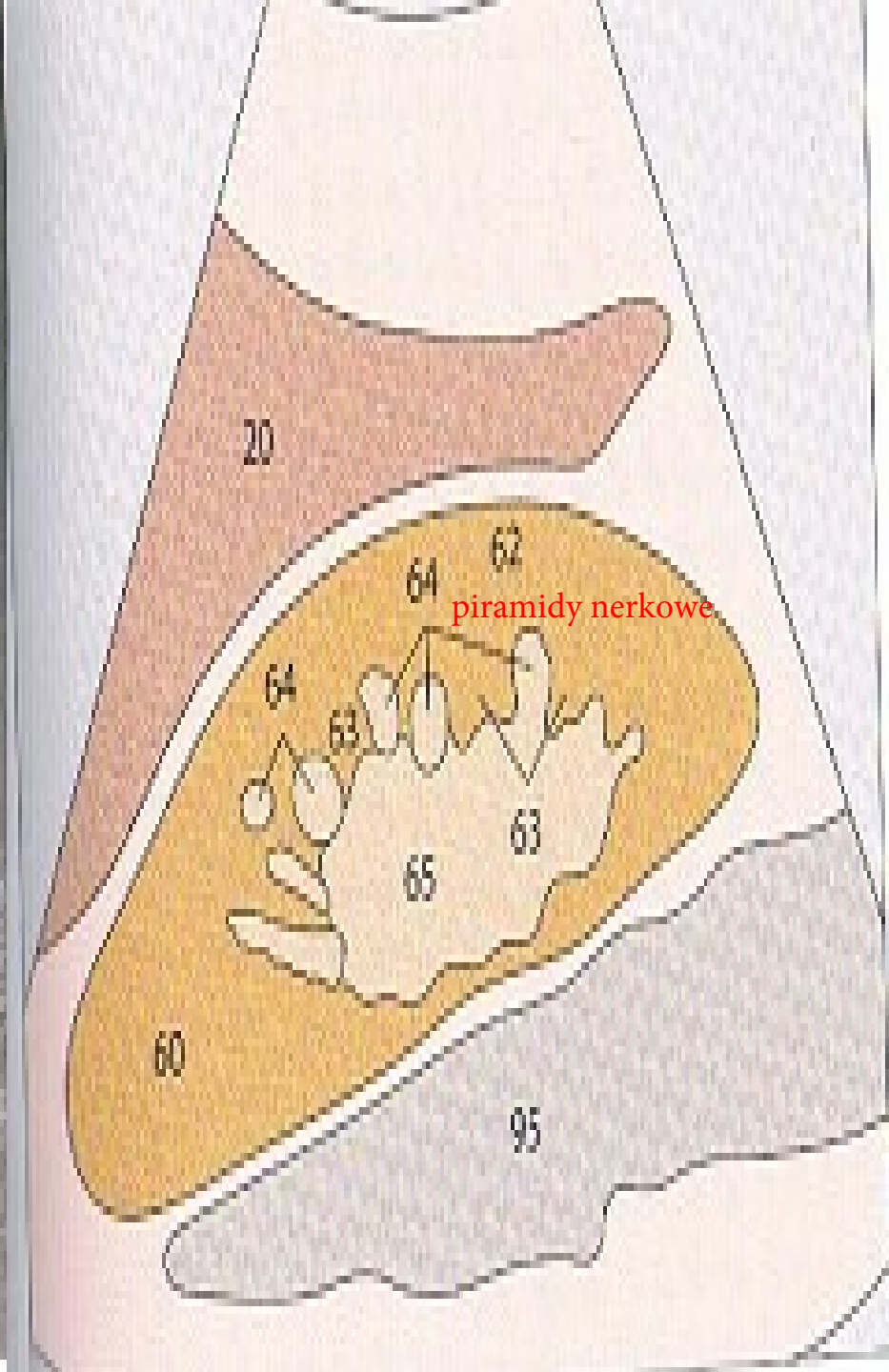
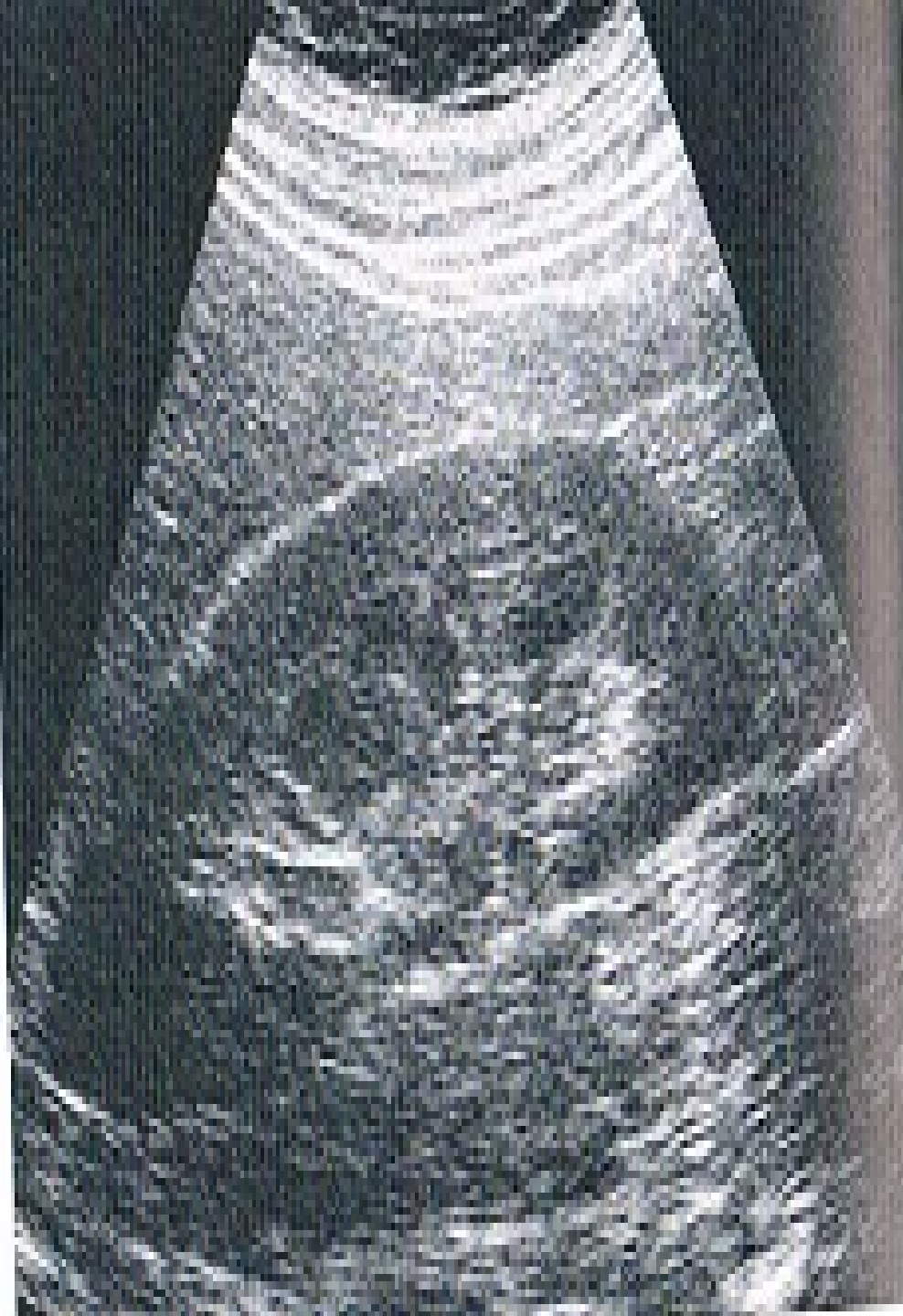miedniczka nerkowa

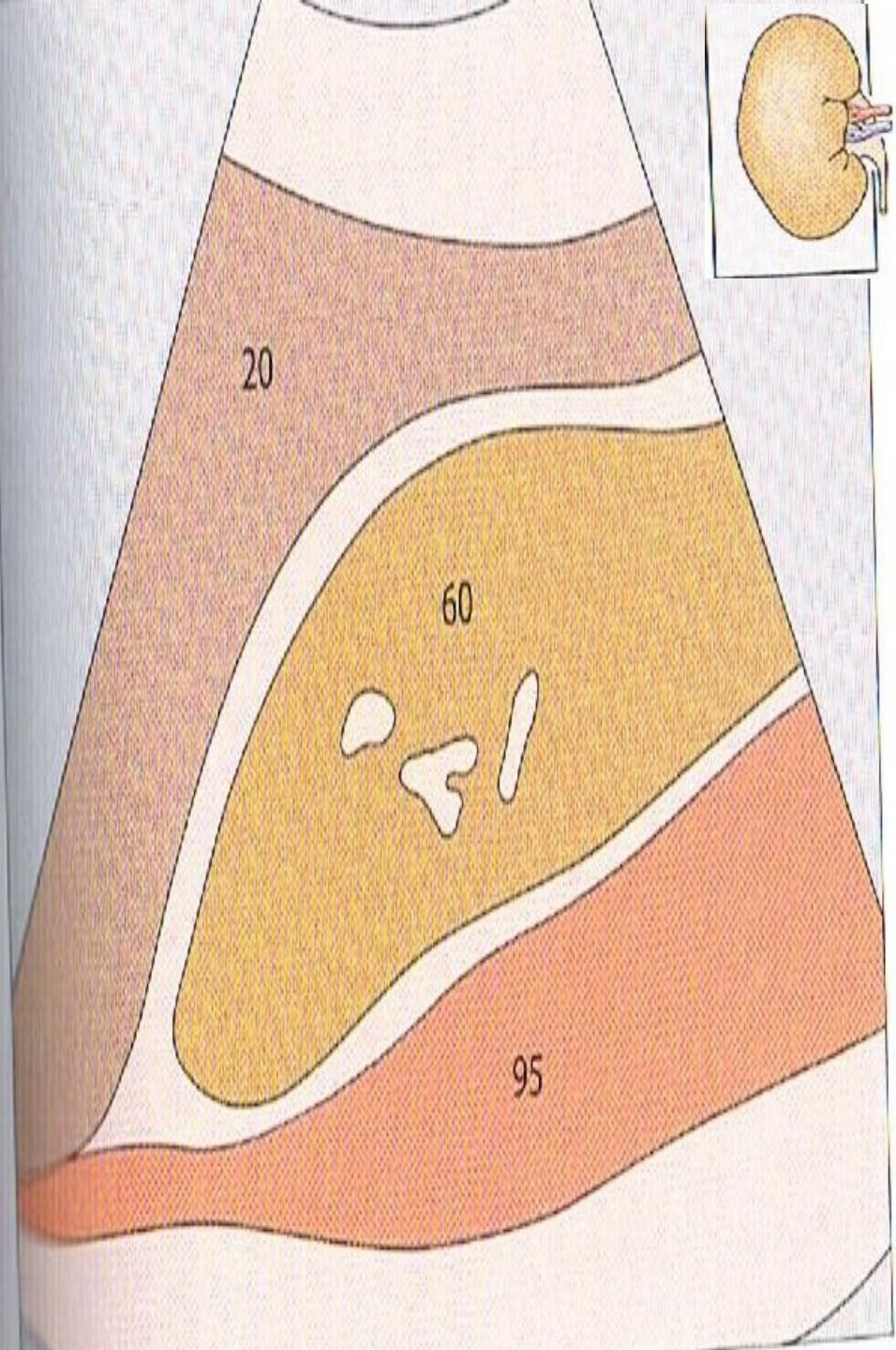
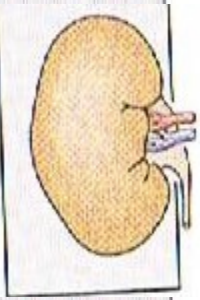
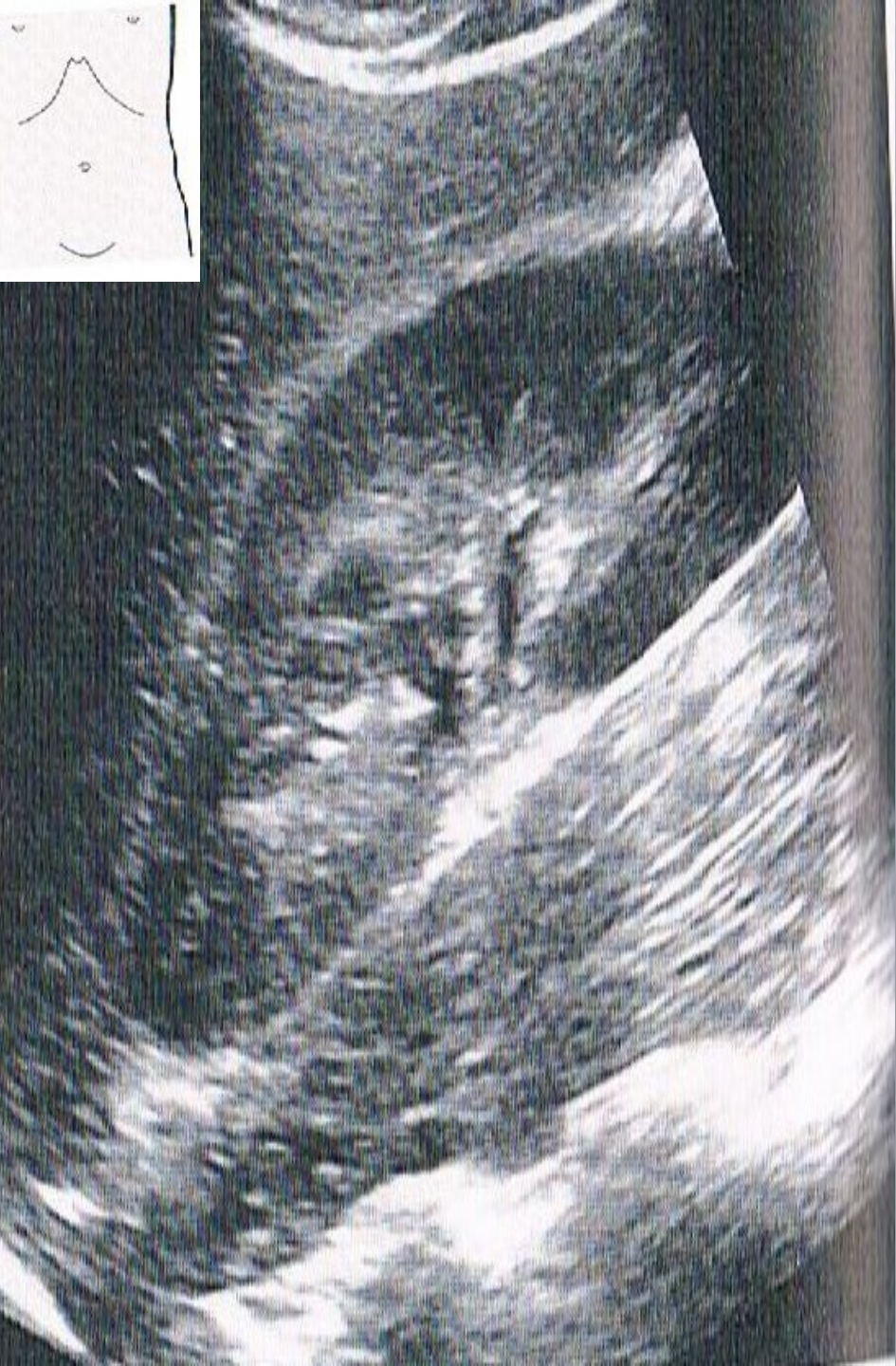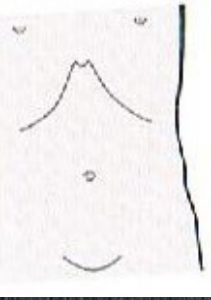tzw. echo centralne nerki

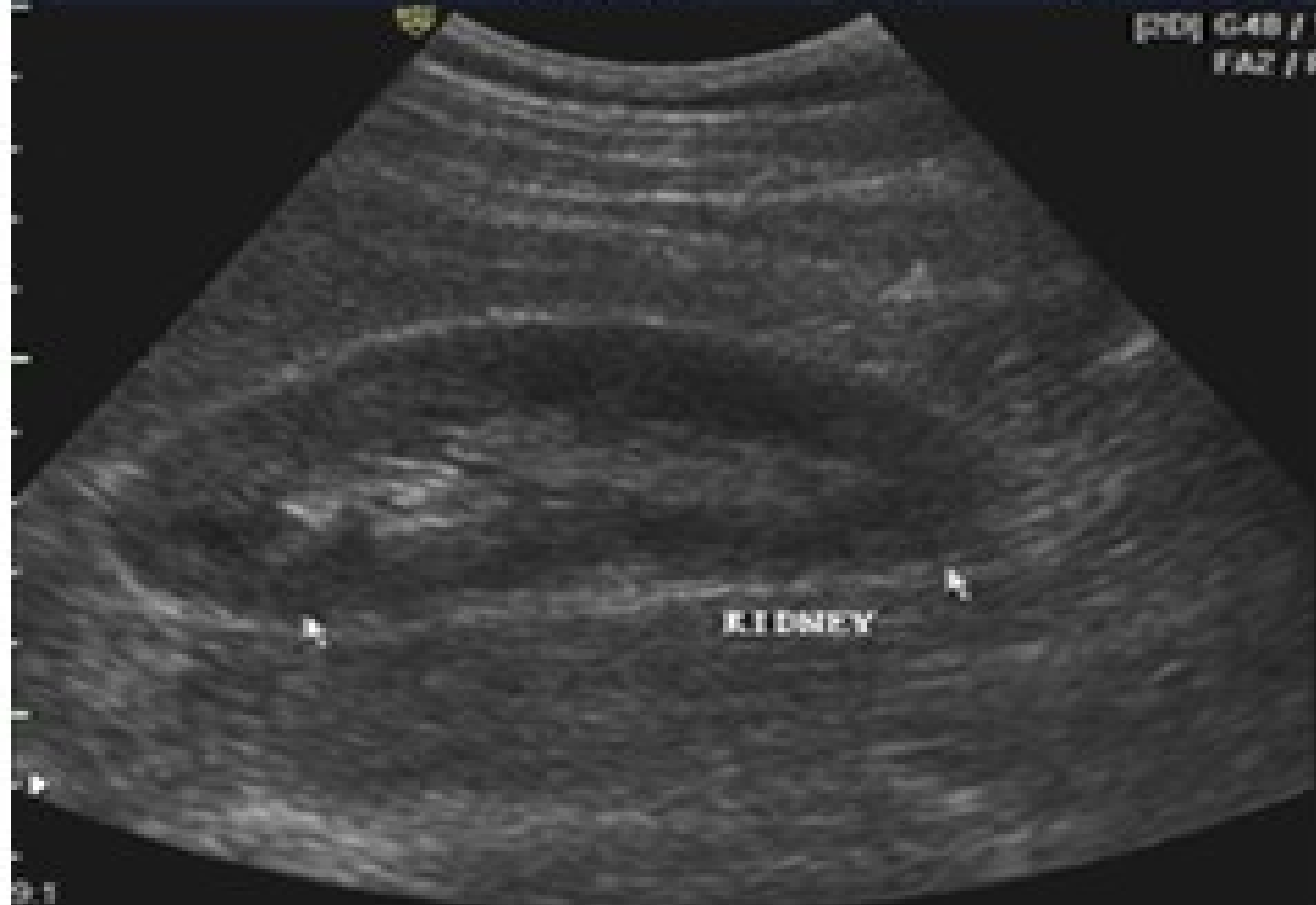61

95

m. lędźwiowy większy

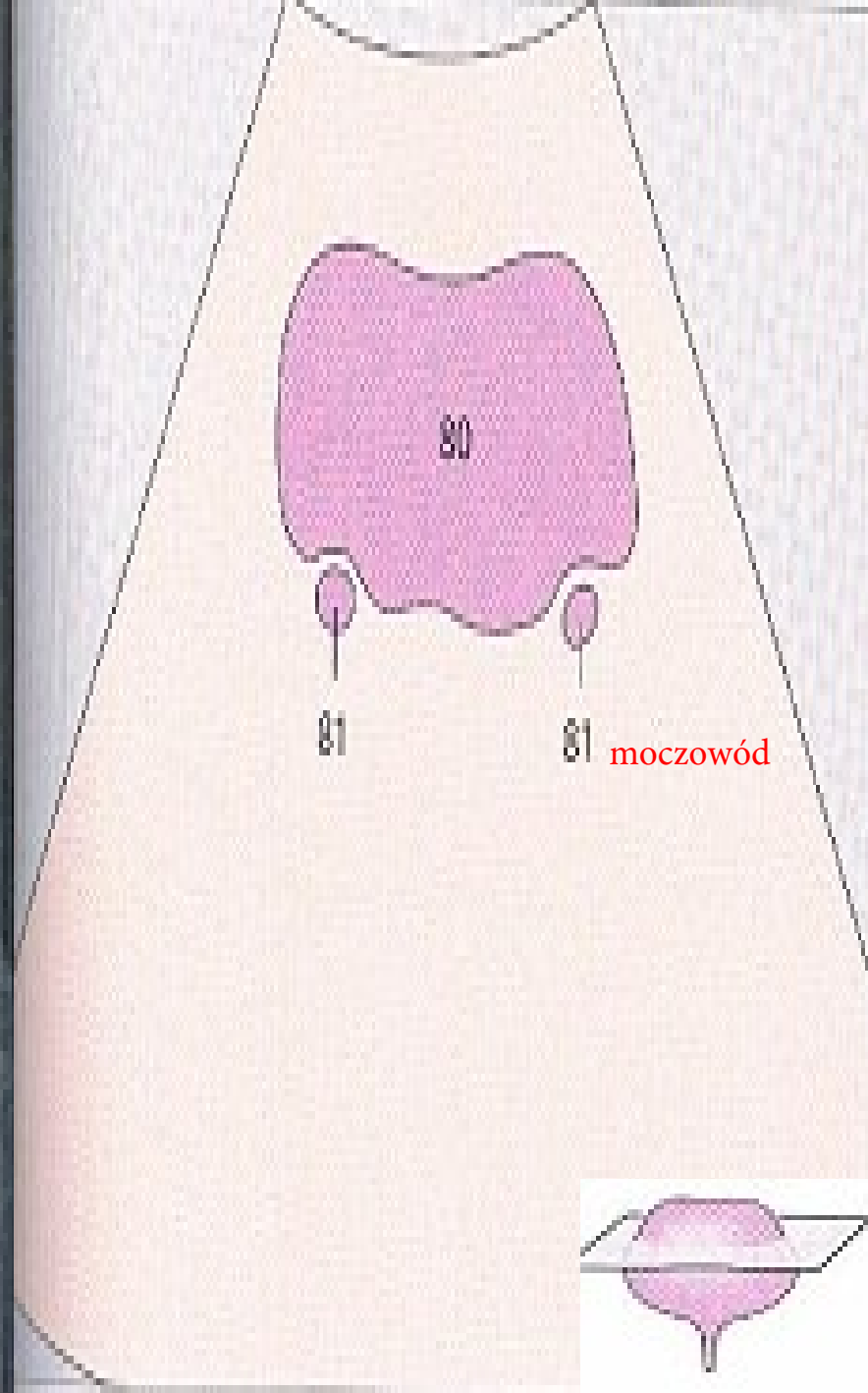
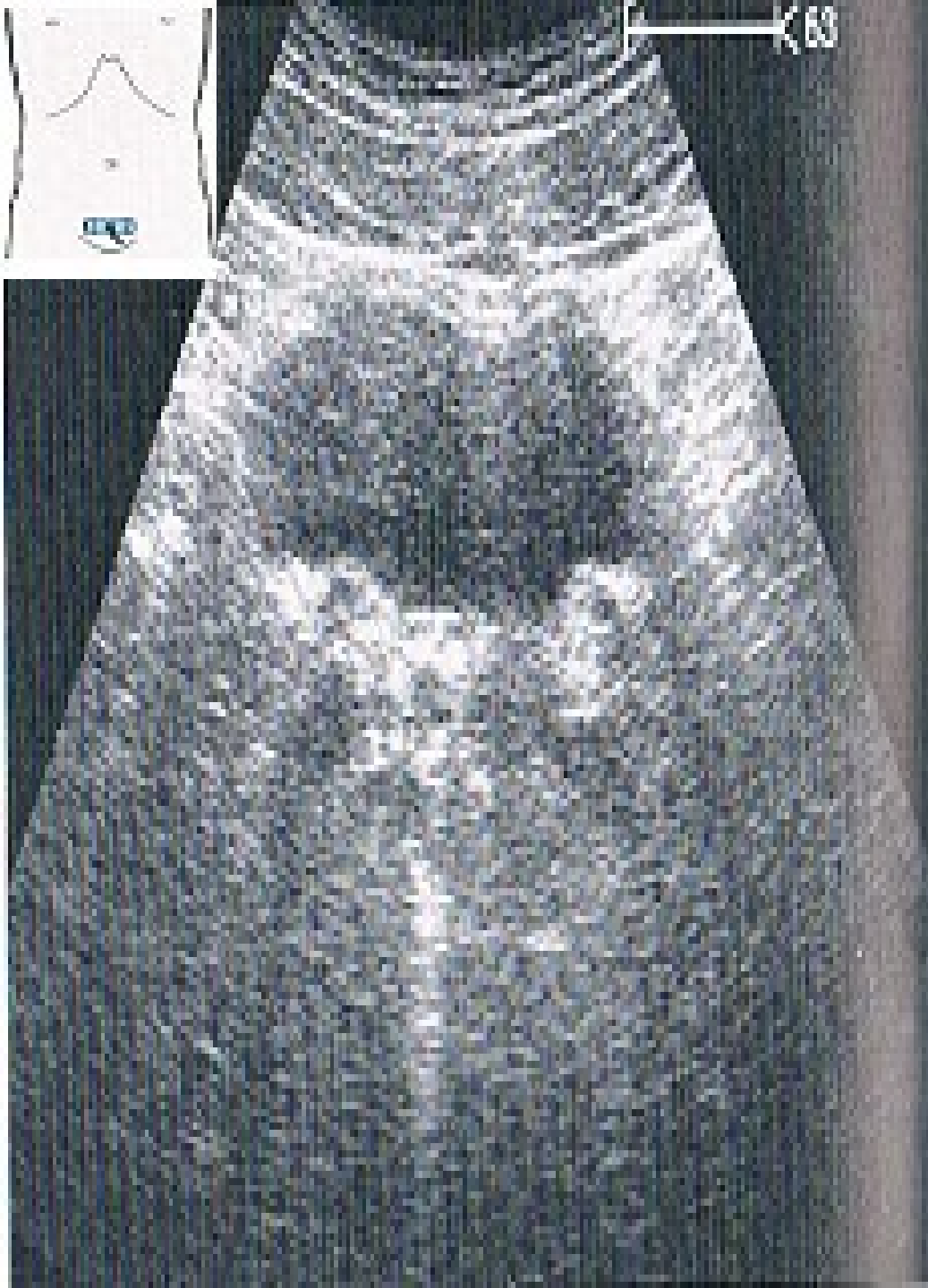








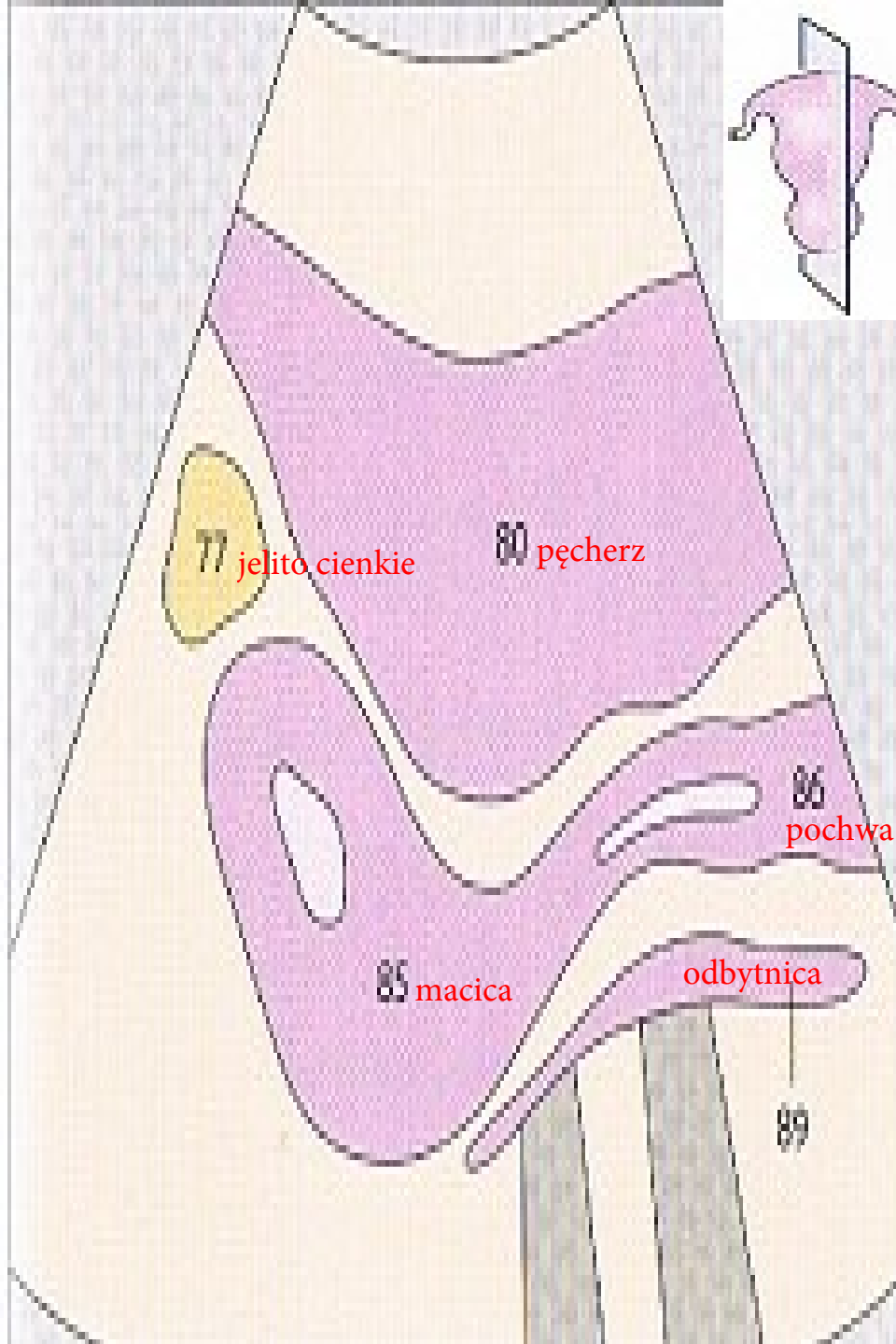
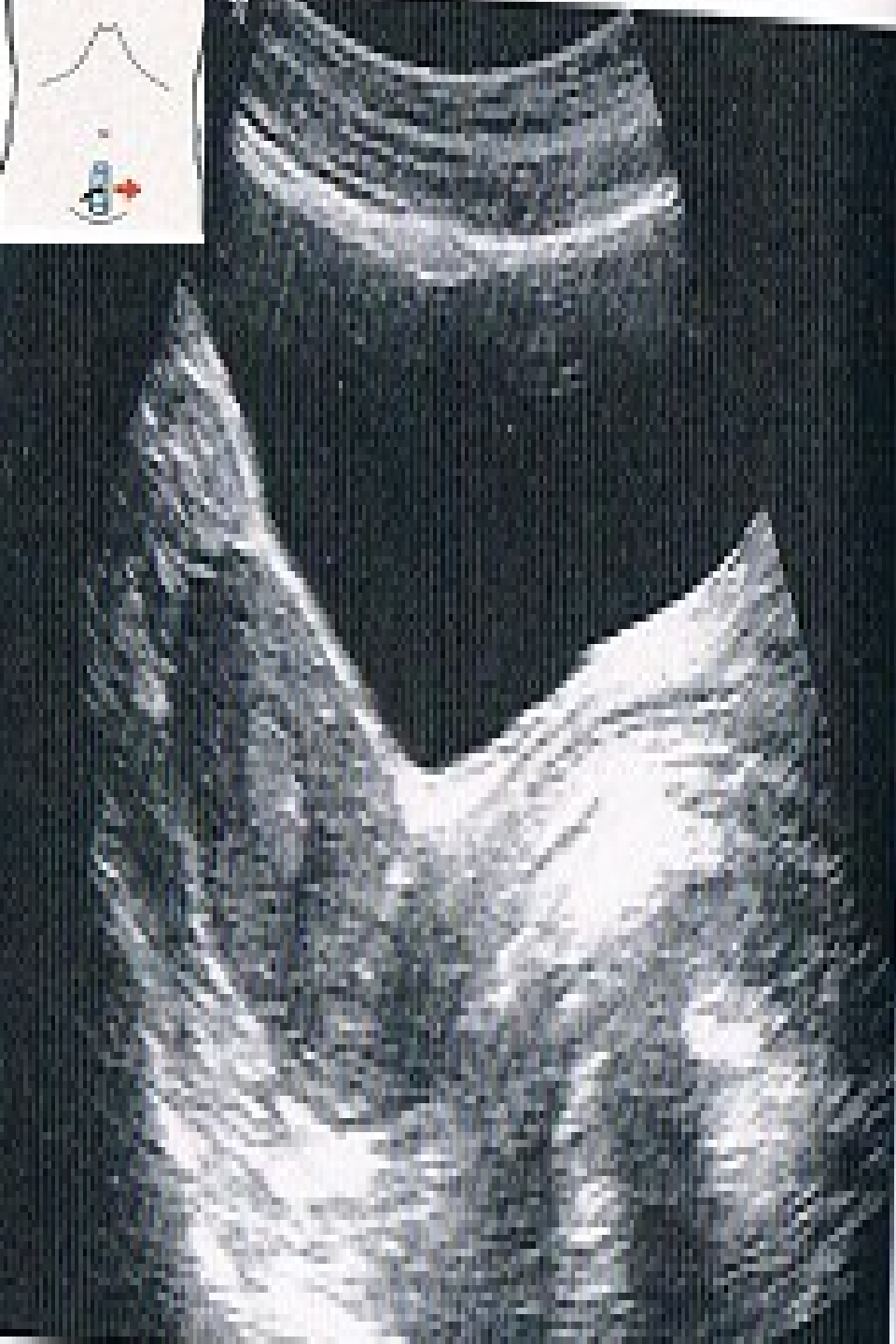- Pęcherz moczowy,  
moczowody



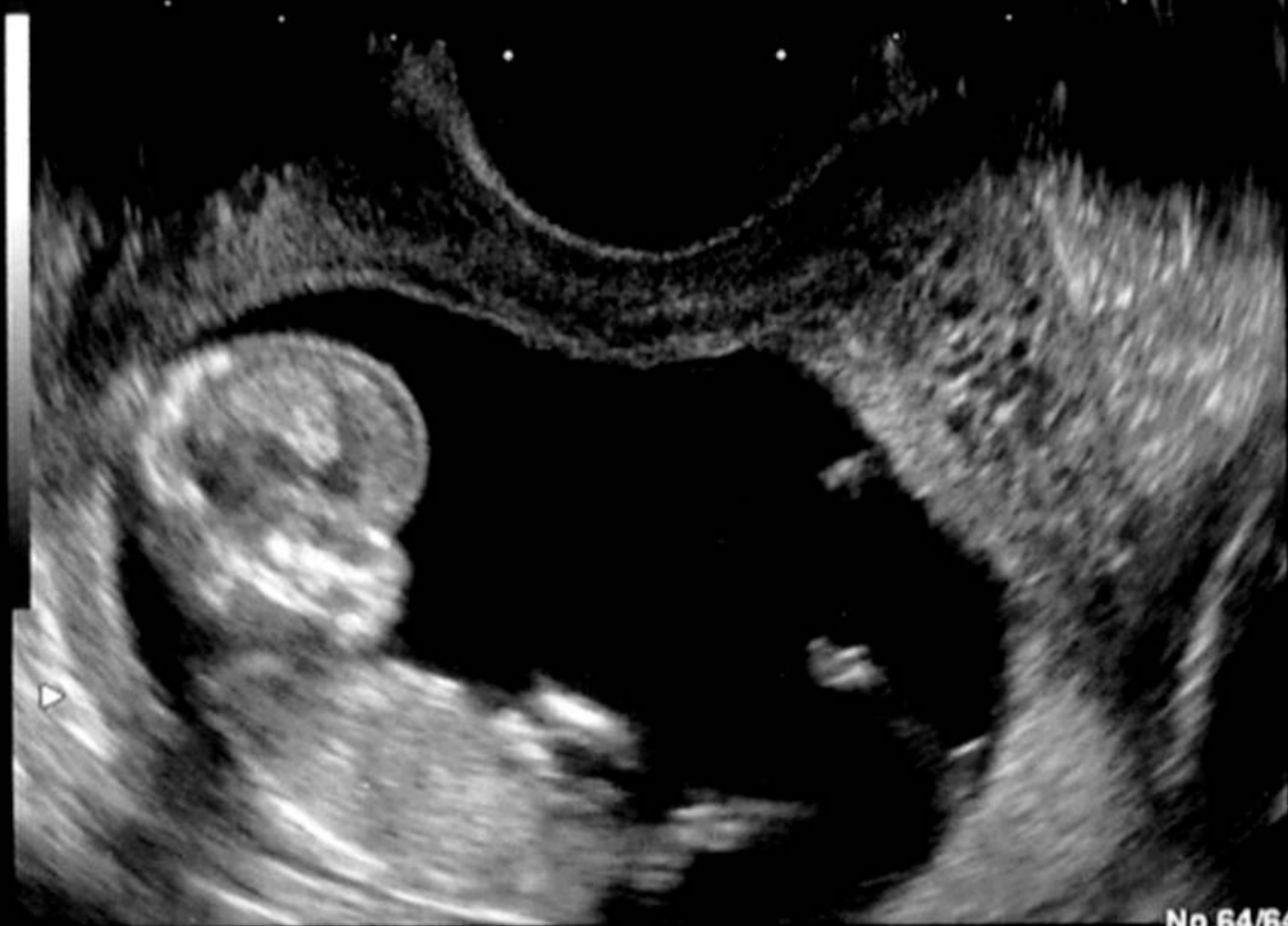

# ■ MACICA





H 000



No.64/64

BG:5 70/HI/2/4/2/A/5

V53W 7.5M Obstetrics 85mm

1 Review 2 SPD; 3 ODM 4  5 Ratio-Area 6 AFI 7 Fetal Para.



## A ponadto...

- Narząd ruchu (stawy, więzadła...)
- Naczynia krwionośne
- Węzły chłonne



# BIBLIOGRAFIA

- Block Berthold, Anatomia ultrasonograficzna, kolorowy atlas. PZWL
- <http://www.ultrasonix.com/applications> !!!
- [www.ultramedica.pl](http://www.ultramedica.pl)