

The background of the slide is a blue surgical drape with various surgical instruments laid out on it. Visible instruments include a scalpel on the left, a pair of forceps at the top, a pair of scissors on the right, and a pair of long-handled forceps at the bottom. The text is overlaid on this background.

# **PRAWIDŁOWE NAZEWNICTWO INSTRUMENTARIUM CHIRURGICZNEGO**

**Adam J. Białas**

Przewodniczący SKN przy

**Klinice Chirurgii i Onkologii Dziecięcej**

Kierownik kliniki: Prof. dr hab.n.med. E. Andrzejewska

Kierownik kursu: dr n.med. J. Jabłoński

A pair of surgical forceps with long handles and curved tips, resting on a blue, textured fabric. A white suture thread is visible in the foreground, looping around the base of the instrument. The background is a solid blue color with some faint, darker blue patterns.

**Znajomość instrumentarium**

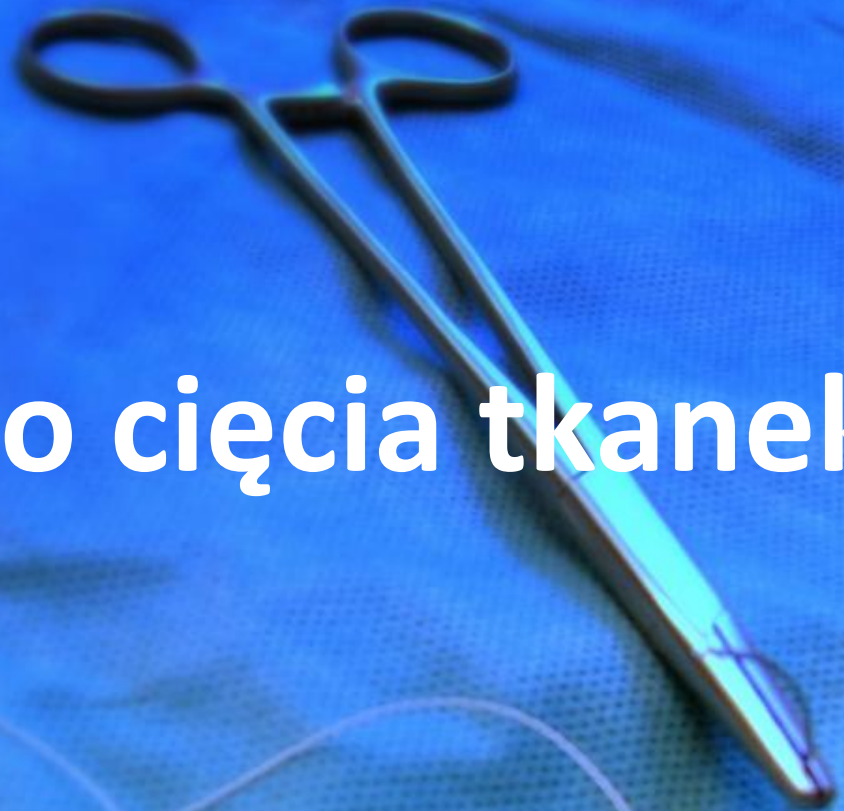
**–**

**tak właściwie po co?**




images8.cafepress.com

# Narzędzia do cięcia tkanek



# SKALPEL



[www.fredaldous.co.uk/shop\\_images/category\\_images/swan-morton-graphic-scalpel.jpg](http://www.fredaldous.co.uk/shop_images/category_images/swan-morton-graphic-scalpel.jpg)

[www.robbsinstruments.com](http://www.robbsinstruments.com)



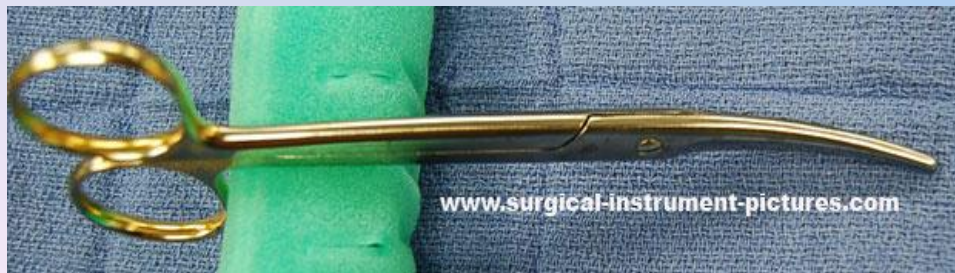# NOŻYCZKI



**Nożyczki Metzenbauma**

[webdematerial.iespana.es](http://webdematerial.iespana.es)

**Nożyczki zakrzywione typu Mayo**



**Nożyczki proste typu Mayo**

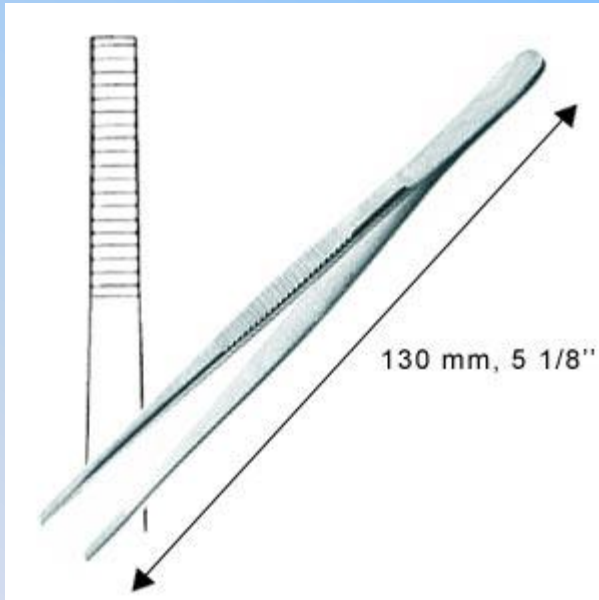


A pair of surgical forceps and a suture thread are shown on a blue, textured fabric background. The forceps are positioned diagonally, with the handles at the top and the jaws pointing towards the bottom right. The suture thread is a thin, light-colored line that loops across the lower half of the image. The text is centered in the middle of the image.

**Narzędzia do  
chwytania tkanek**

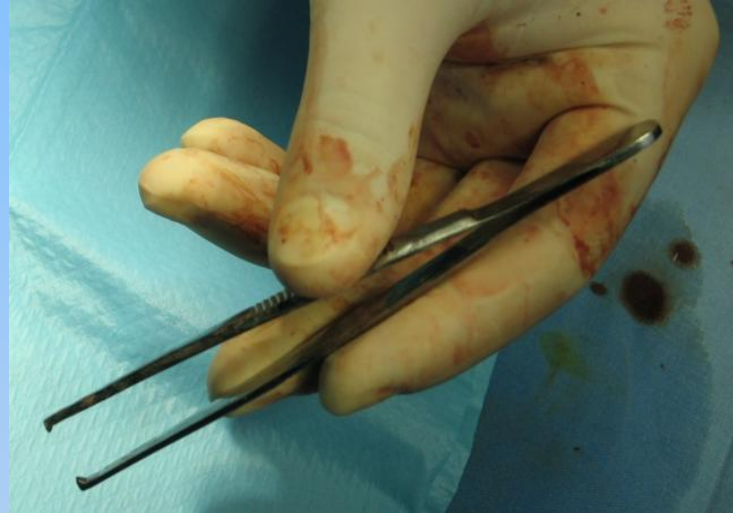# PINCETY

**Pinceta anatomiczna**



[www.targimedyczne.pl/images](http://www.targimedyczne.pl/images)

**Pinceta chirurgiczna**



[med.pam.szczecin.pl/~michals/chirurgia/foto/szycie](http://med.pam.szczecin.pl/~michals/chirurgia/foto/szycie)



**Pinceta naczyniowa DeBakeya**



**Pinceta Bonneya**

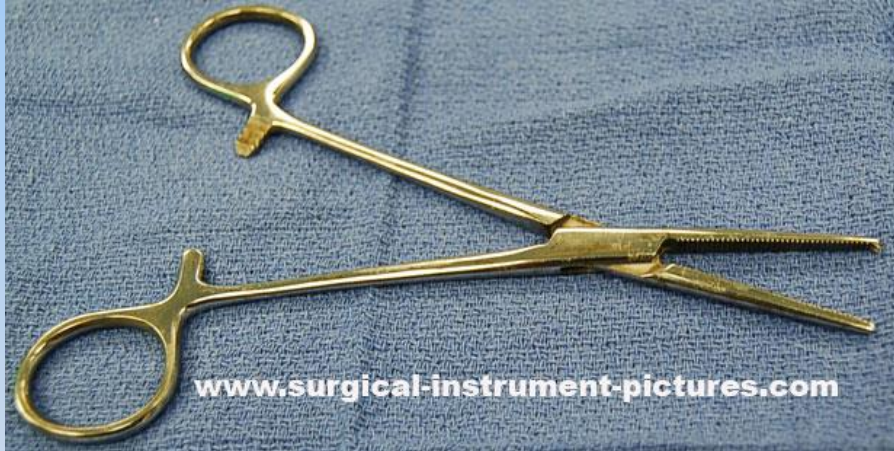

**Pinceta Rosyjska**

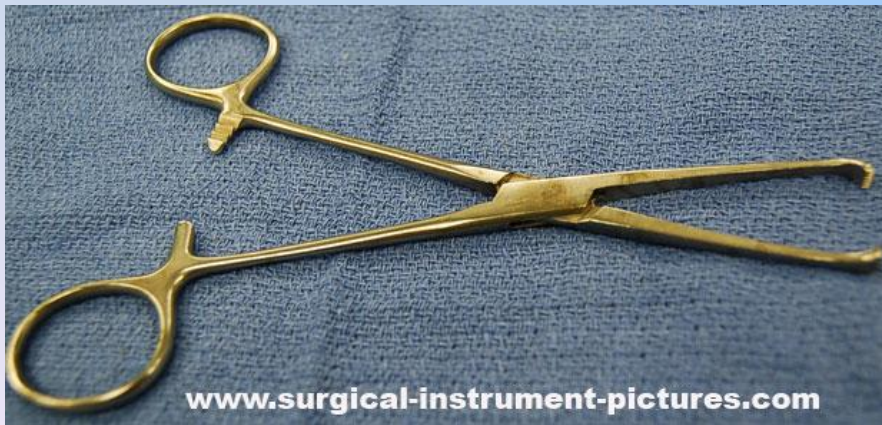




# KLESZCZYKI



**Kocher**

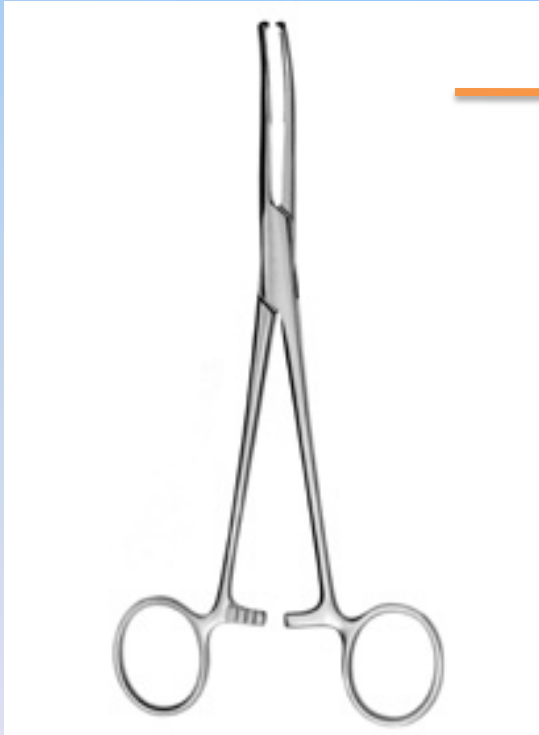

**Chaput ( Allis )**

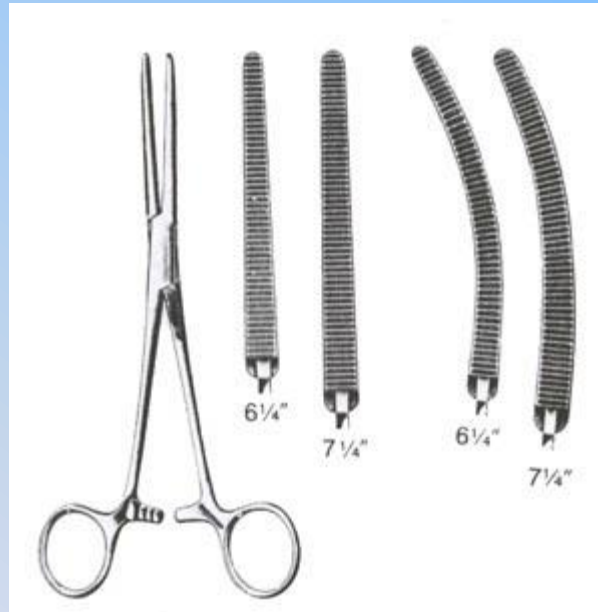

# KLESZCZYKI 2

**Mikulicz**

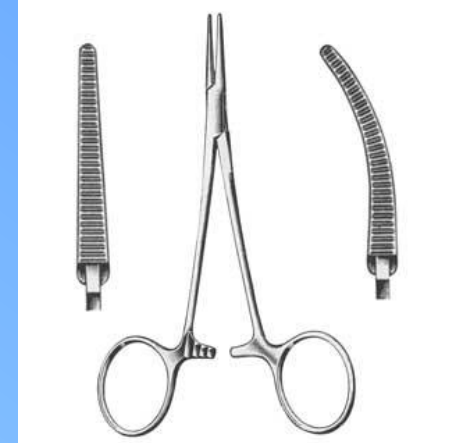

**Péan**

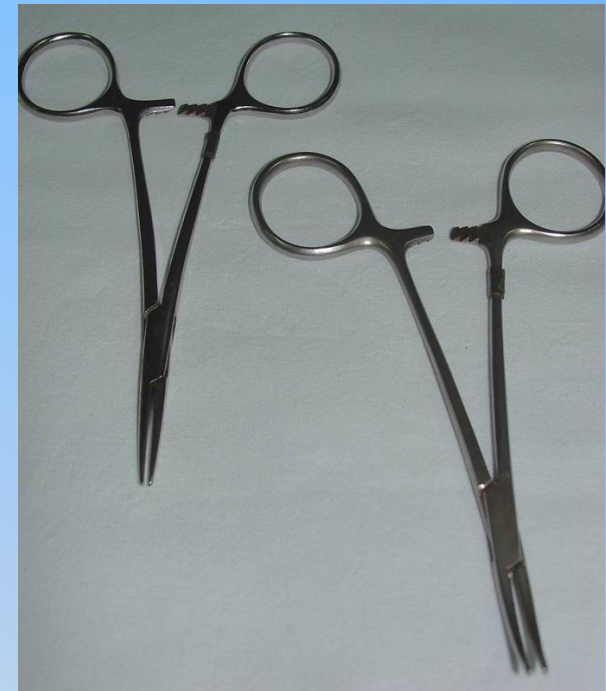

[www.advancedsurgicaldirect.com](http://www.advancedsurgicaldirect.com)

**Moskit**



[www.ups.edu/.../mosquito-forceps.jpg](http://www.ups.edu/.../mosquito-forceps.jpg)



[www.echirurgia.pl/technika/narzedzia\\_klasyczn..](http://www.echirurgia.pl/technika/narzedzia_klasyczn..)

[webdematerial.iespana.es](http://webdematerial.iespana.es)

# KLEMY

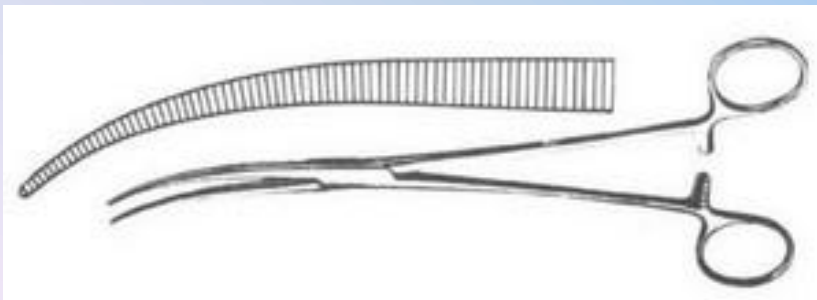
rmson.com

www.germedusa.com/images

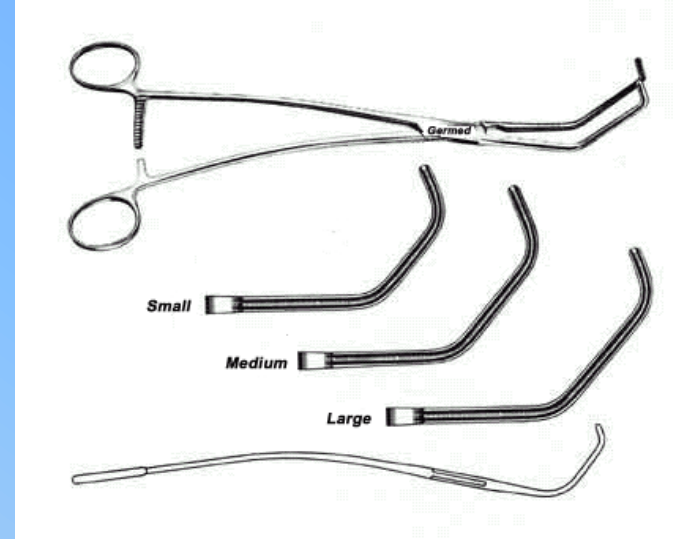


**Klem naczyniowy DeBakeya**


**Klem jelitowy Sarota**




www.wholesalesurgicalinstruments.com/images



**Klem naczyniowy Satinsky'ego**  
**Klem naczyniowy bulldog**



www.ahmadsurgical.com/images/AS-131-614.jpg

A pair of surgical forceps and a suture thread are shown on a blue, textured fabric background. The forceps are positioned diagonally, with the handles at the top and the jaws pointing towards the bottom right. The suture thread is a thin, light-colored line that loops across the lower portion of the image. The text is centered in the middle of the frame.

# Narzędzia do odciągania tkanek

# Haki

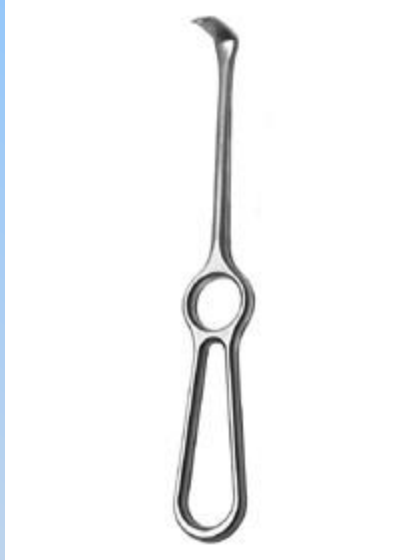
Richardson

Hak skórny ostry



[www.ups.upenn.edu](http://www.ups.upenn.edu)

Langenbeck



Hak brzuszny typu Mayo

Farabeuf

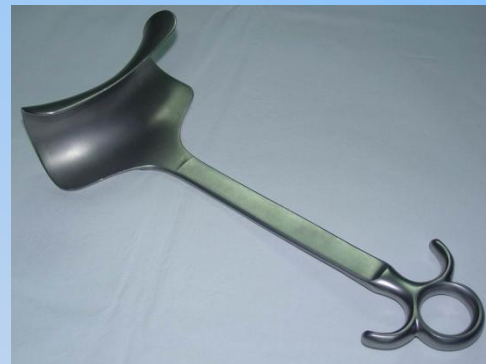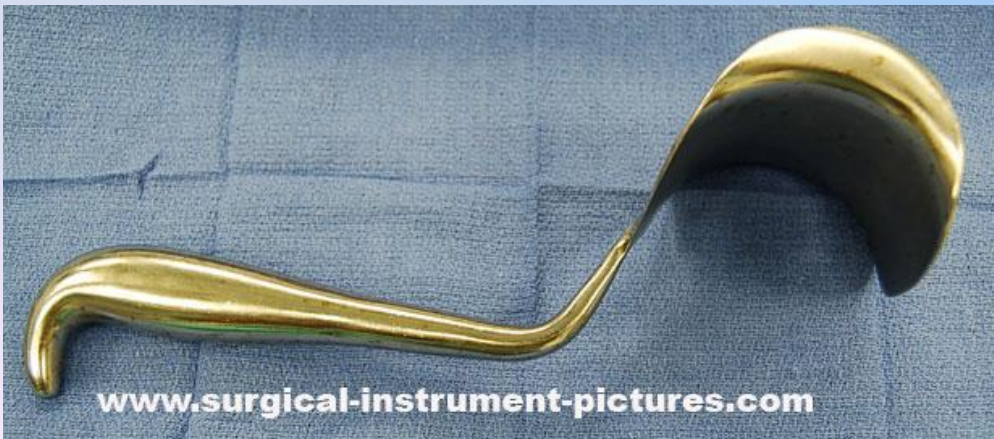


[webdematerial.iespana.es](http://webdematerial.iespana.es)

Reverdin



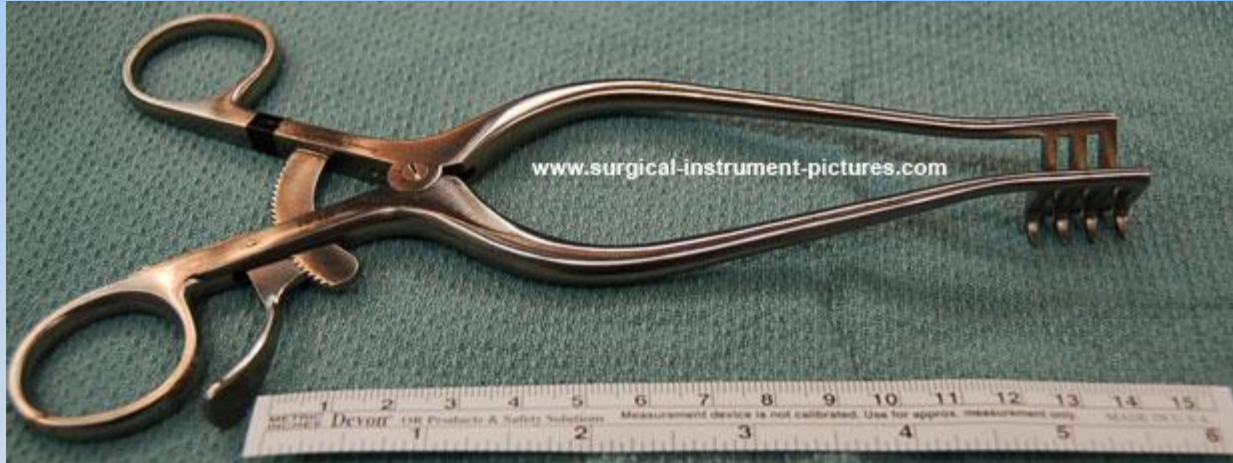[medical-tools.com](http://medical-tools.com)



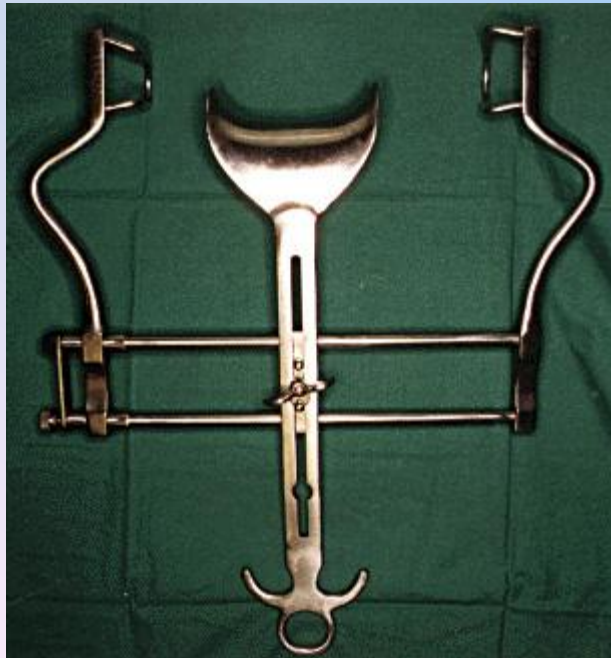Hak powłokowy

[webdematerial.iespana.es](http://webdematerial.iespana.es)

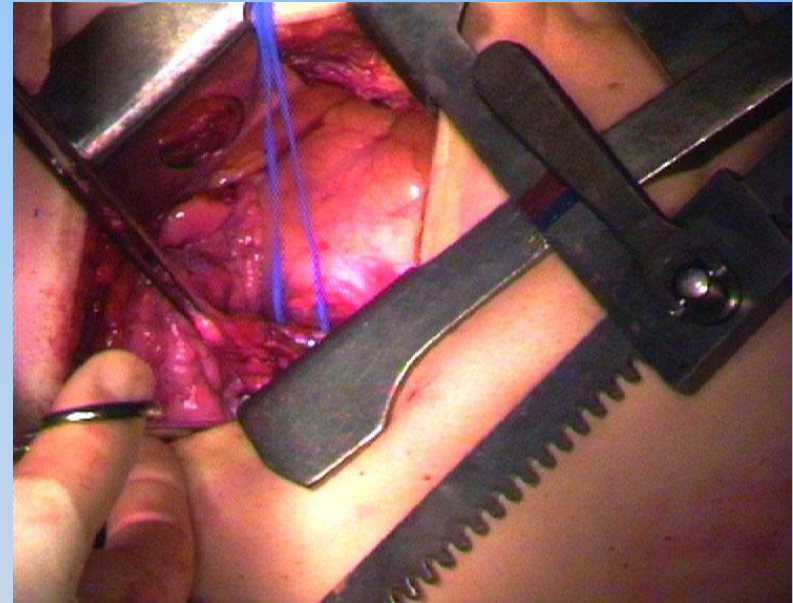
# Haki 2



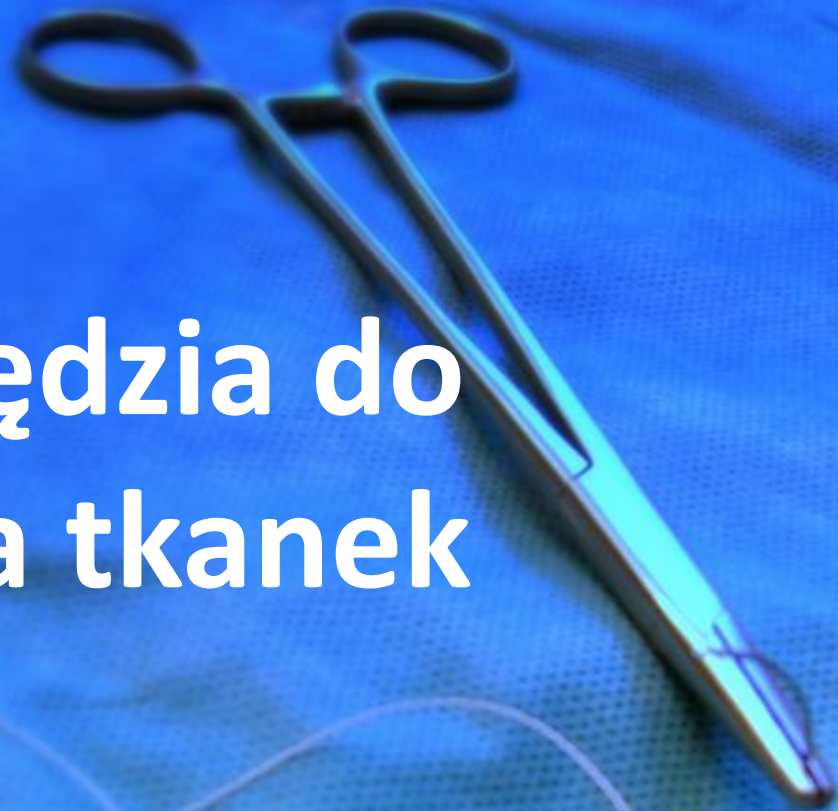
**Weitlaner**



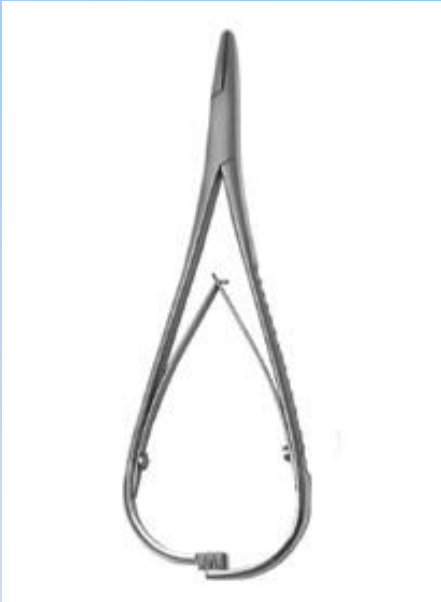**Balfour**



# Narzędzia do szycia tkanek

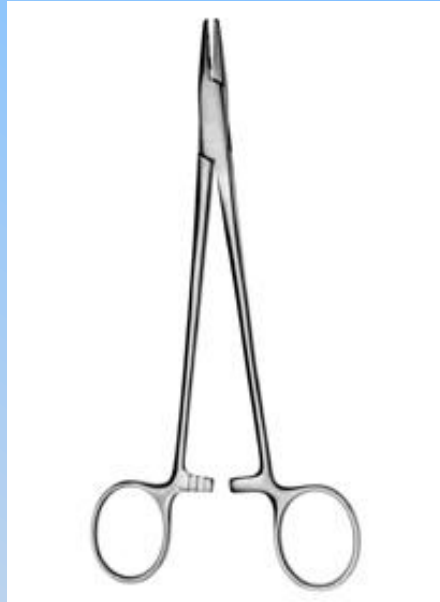

# IMADŁA

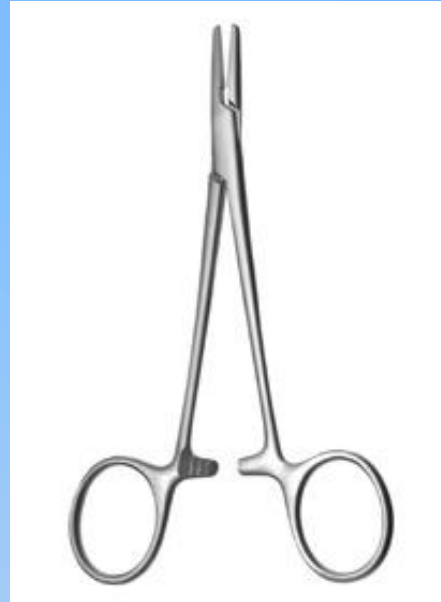

**Mathieu**

[www.echirurgia.pl/technika/narzedzia\\_klasyczne\\_braun](http://www.echirurgia.pl/technika/narzedzia_klasyczne_braun)



**Hegar**



**Halsey**



**Collier**

[arsaenterprises.com](http://arsaenterprises.com)



**Dziękuję za uwagę**

